

07th November 2023

The General Manager,
Department of Corporate Services
Bombay Stock Exchange Ltd (BSE)
Phiroze Jheejheebhoy Towers,
Dalal Street,
Mumbai - 400 001.
Scrip Code - 543308
ISIN: INE967H01017

The Manager,
Listing Department
National Stock Exchange of India Limited,
Exchange Plaza, 5th Floor,
Plot No.C/1, 'G' Block,
Bandra - Kurla Complex,
Mumbai - 400 051.
Symbol - KIMS
ISIN: INE967H01017

Dear Sir,

Sub: Investor Presentation

Pursuant to Regulation 30 of the Securities and Exchange Board of India (Listing Obligations and Disclosure Requirements) Regulations, 2015 please find enclosed herewith the Investor Presentation on un-audited (Standalone & Consolidated) financial results of the Company for the quarter and half-year ended 30th September 2023.

The said presentation is being uploaded on the website of the Company i.e., <https://www.kimshospitals.com/investors/Disclosures> under Regulation 46 of SEBI (LODR) Regulations, 2015/Analysts Calls schedule, PPT & Transcripts/PPT's.

We request you to take this on record.

Thanking you,

Yours truly,

For Krishna Institute of Medical Sciences Limited

MANTHA Digitally signed by
UMASHAN MANTHA
KAR UMASHANKAR
Date: 2023.11.07
17:07:17 +05'30'

Umashankar Mantha

Company Secretary & Compliance Officer

Enclosed: As above



REAL
WEALTH IS
**GOOD
HEALTH**

Q2 FY24 UPDATE

Driven by a Vision

VISION:

To be the most preferred healthcare services brand by providing affordable care and best clinical outcomes to patients.

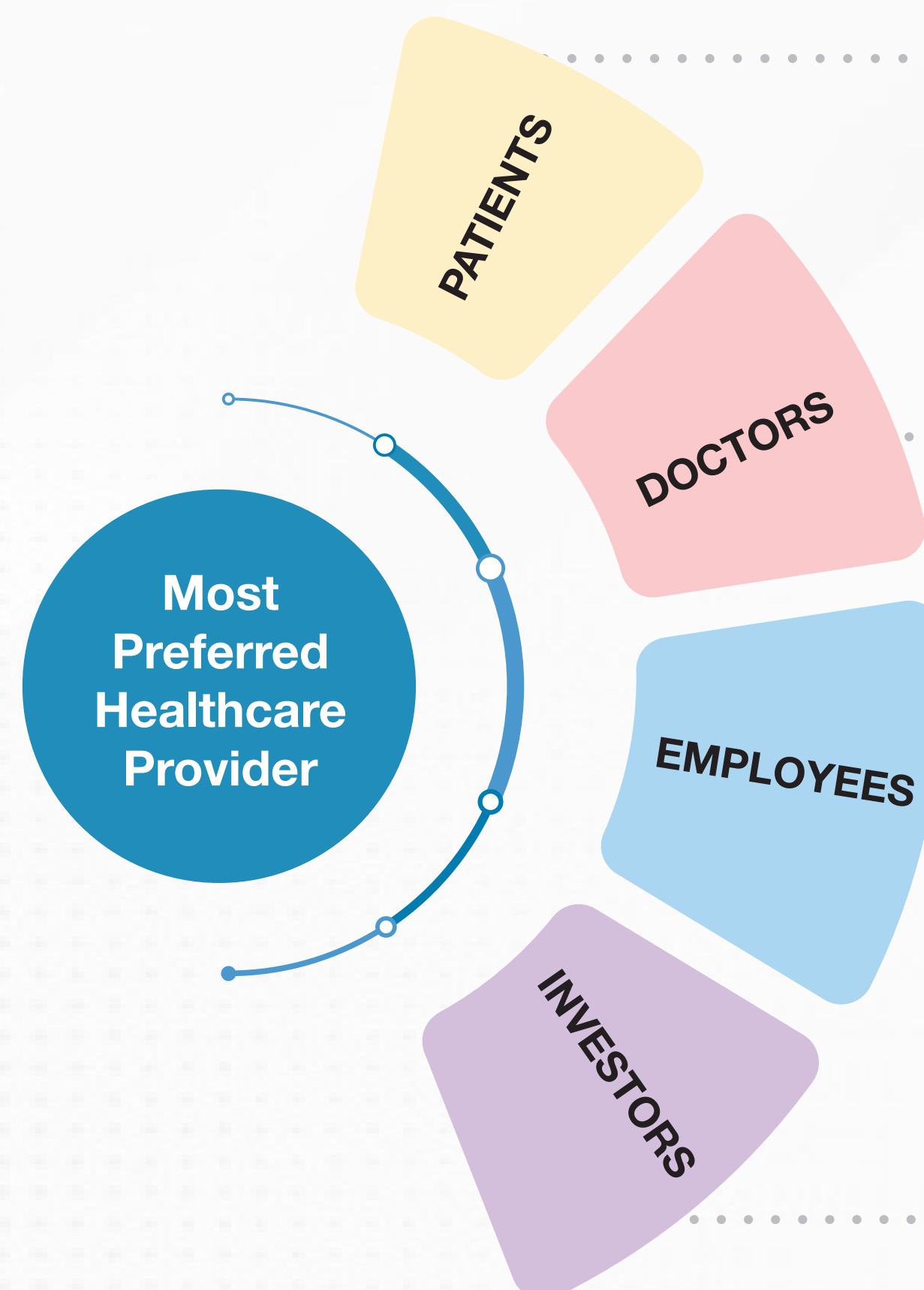
And to be the best place to work for doctors and employees.

OUR MISSION:

Provide affordable quality care to our patients with patient-centric systems and processes.

Enable clinical outcome-driven excellence by engaging modern medical technology.

Provide a strong impetus for doctors to pursue academics and medical research.



Affordable Quality Care
Best-in-Class Facilities
Patient Centric Systems & Processes

Clinical Outcome Driven Excellence
Latest Medical Technology
Strong Academics & Research Oriented

Enriching Atmosphere
Collaborative Culture
Growth Driven Career Approach

Transparent Governance
Strong Operational Performance
Consistent Growth

Multi Specialty Care

Brain

- Neurology
- Neurosurgery
- Psychiatry
- Neuro Rehabilitation

Heart

- Cardiology
- Cardiac Surgery
- Vascular Surgery
- Heart Transplant
- Cardio Rehabilitation

Lung

- Pulmonology
- Interventional Pulmonology
- Thoracic surgery
- Lung Transplant

ENT

- Ear
- Nose
- Throat
- Head and Neck Surgery

Eyes

- Ophthalmology

Gastro Intestinal Tract

- Medical Gastroenterology
- Surgical Gastroenterology
- Hepatobiliary Pancreatic Surgery
- Liver Transplant
- Bariatric Surgery

Genito Urinary Tract

- Nephrology
- Urology
- Andrology
- Renal Transplant
- Gynecology
- Urogynecology
- IVF and ART
- Fetal Medicine
- Obstetrics

Oncology

- Medical Surgical and Radiation
- BMT and Hematology

Bones and Spine

- Orthopedics
- Arthroscopic Surgery
- Spine Surgery
- Ortho Rehabilitation

Skin

- Dermatology
- Cosmetology
- Plastic and Reconstructive Surgery

Orthodontics

- Maxillo Facial Surgery

Anaesthesia

- OT Anaesthesia
- Day care Anaesthesia
- Pain Medicine

General Specialities

- Internal Medicine
- General Surgery
- Diabetology & Endocrinology

Pediatrics

- Pediatrics & Pediatric Sub Specialities
- Neonatology

Radiology

- Imaging
- Interventional Radiology

Lab Services

- Pathology
- Microbiology
- Biochemistry
- Molecular Biology
- Clinical Hematology

Critical Care Services

- ICU
- CTICU
- SICU
- NICU
- PICU
- Neuro ICU
- ECMO ICU
- Post Transplant ICU

Hospital Infection Control

- Clinical Infectious Diseases

Maharashtra

- Nagpur (334)
- Nashik (Under Construction)
- Thane (Under Construction)

Telangana

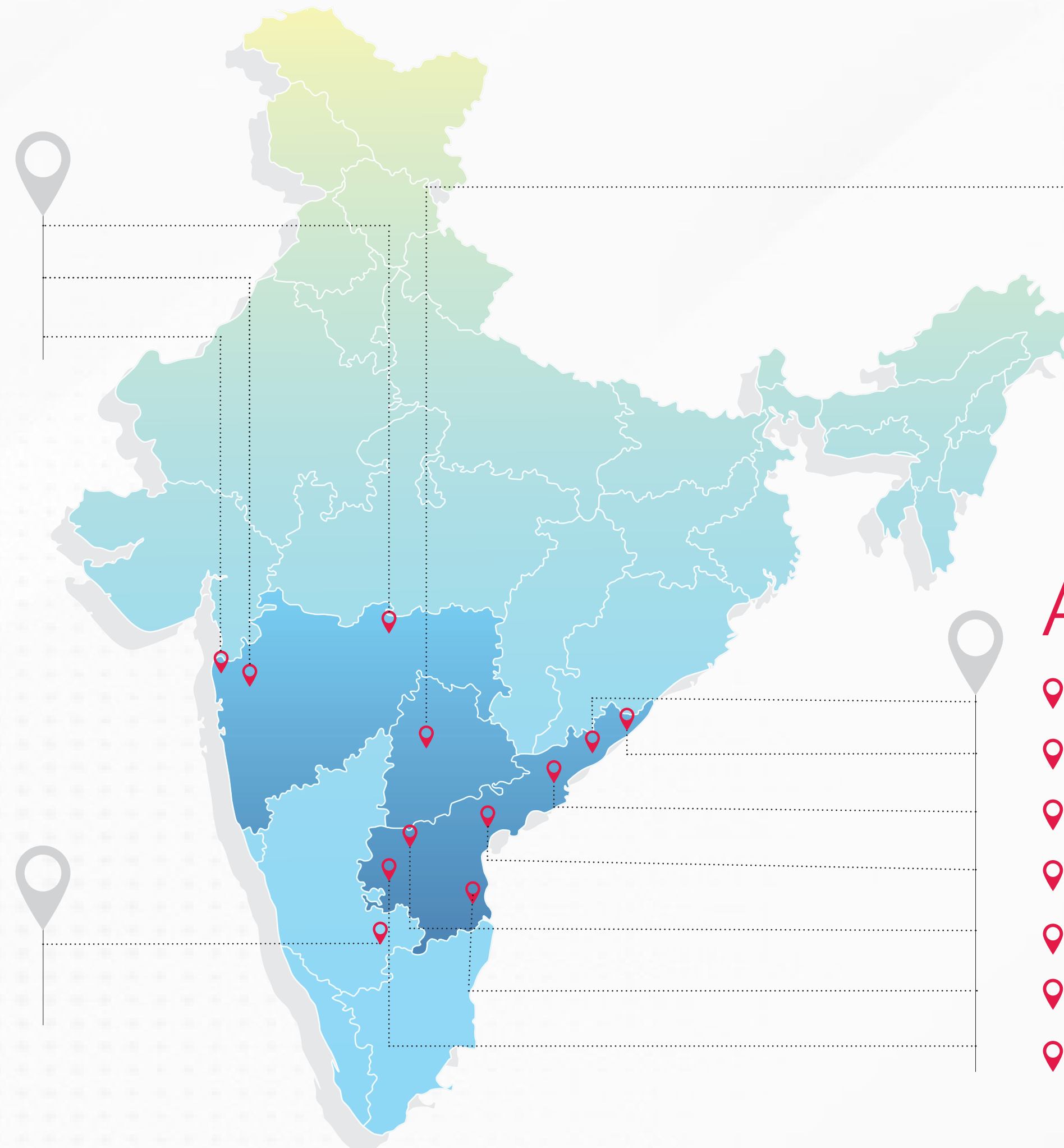
- Secunderabad (1000)
- Paradise Circle (290)
(Shifting to Begumpet)
- Kondapur (200)
- Gachibowli (237)

Karnataka

- Bengaluru
(Under Construction)


Andhra Pradesh

- Visakhapatnam (469)
- Srikakulam (200)
- Rajahmundry (195)
- Ongole (350)
- Kurnool (200)
- Nellore (250)
- Anantapur (250)



Dr. B. Bhaskar Rao - Visionary Behind KIMS

Chairman & Managing Director



A legend in CT Surgery, Dr. Bollineni Bhaskar Rao {MBBS, MS, DNB (CT Surgery)} is one of the very few Cardio-Thoracic Surgeons in the country, who performed over 30000 surgeries in his career spanning over more than 25 years.

Well known in the medical fraternity for his passion towards his profession, Dr. Rao started his entrepreneurial journey at “Mahavir Cardio Vascular Centre” in Hyderabad with 50 beds and performed heart surgeries at an unimaginable low cost of just Rs. 45,000 only. Dr. Rao never turned away any patient from the hospital for want of money.

The brand “Krishna Institute of Medical Sciences”, under Dr. B. Bhaskar Rao’s aegis began its journey in 2004 with a 300 bed hospital on par with the then established hospitals of Hyderabad in professional excellence, the state of art technology and infrastructure facilities.

Today KIMS is spread across 12 locations in Telangana, Andhra Pradesh and Maharashtra.

Dr. Bhaskar Rao was instrumental in formulating Rajiv Gandhi Aarogyasri scheme, first time launched in Andhra Pradesh in 2007 for providing health care to the poorest of the poor.

This prestigious scheme has won him accolades from all quarters of the country and the world. He was the chief architect of Aarogyashri scheme for both creating it and implementing it successfully.

This well formulated scheme has become so popular that the other States in India have emulated it time and again.

Dr. Abhinay Bollineni

Chief Executive Officer



Dr. Abhinay Bollineni joined KIMS Hospitals in 2013 and spent the next couple of years in Hospital Operations before taking charge of Strategy & Marketing for the Group in 2015.

In a short span of 5 years, KIMS expanded and opened five additional units (Kondapur, Visakhapatnam, Anantapur, Ongole, and Kurnool). Shortly after that, he was appointed as the CEO in 2019. The recent acquisitions led by him were of Sunshine Hospitals, Hyderabad and Kingsway Hospitals, Nagpur.

Dr. B. Abhinay completed MBBS from the Deccan Medical College, Hyderabad, in 2010. He was the lone qualified medical practitioner from India to be selected by the office of Hillary Clinton in 2011, where he participated in the 'International Visitor Leadership Program on Oncology: Research, Prevention and Treatment' held by the US Department of State

He was named in Business World's "BW 40 Under 40" list in 2019.

Under his stewardship, KIMS Hospitals got successfully listed on the Stock Exchanges in India in 2021.

Dr. Abhinay is passionate about using technology to enhance patient experience and clinical care. Towards this, he has spearheaded vital initiatives such as Financial counseling tool which uses AI to help patients with surgery costings among many others

Board of Directors



Dr. Bhaskara Rao Bollineni
Chairman & Managing Director



Dr. Abhinay Bollineni
Chief Executive Officer



Mrs. Anitha Dandamudi
Whole-time Director



Shantanu Rastogi
Non-Executive Director



Mr. Rajeswara Rao G
Independent Director,
Chairman (Stakeholders'
Relationship Committee)



Mr. Saumen Chakraborty
Independent Director,
Chairman (Audit Committee)



Mr. Pankaj Vaish
Independent Director,
Chairman (Nomination &
Remuneration Committee)



Mr. Venkata Ramudu Jasthi
Independent Director

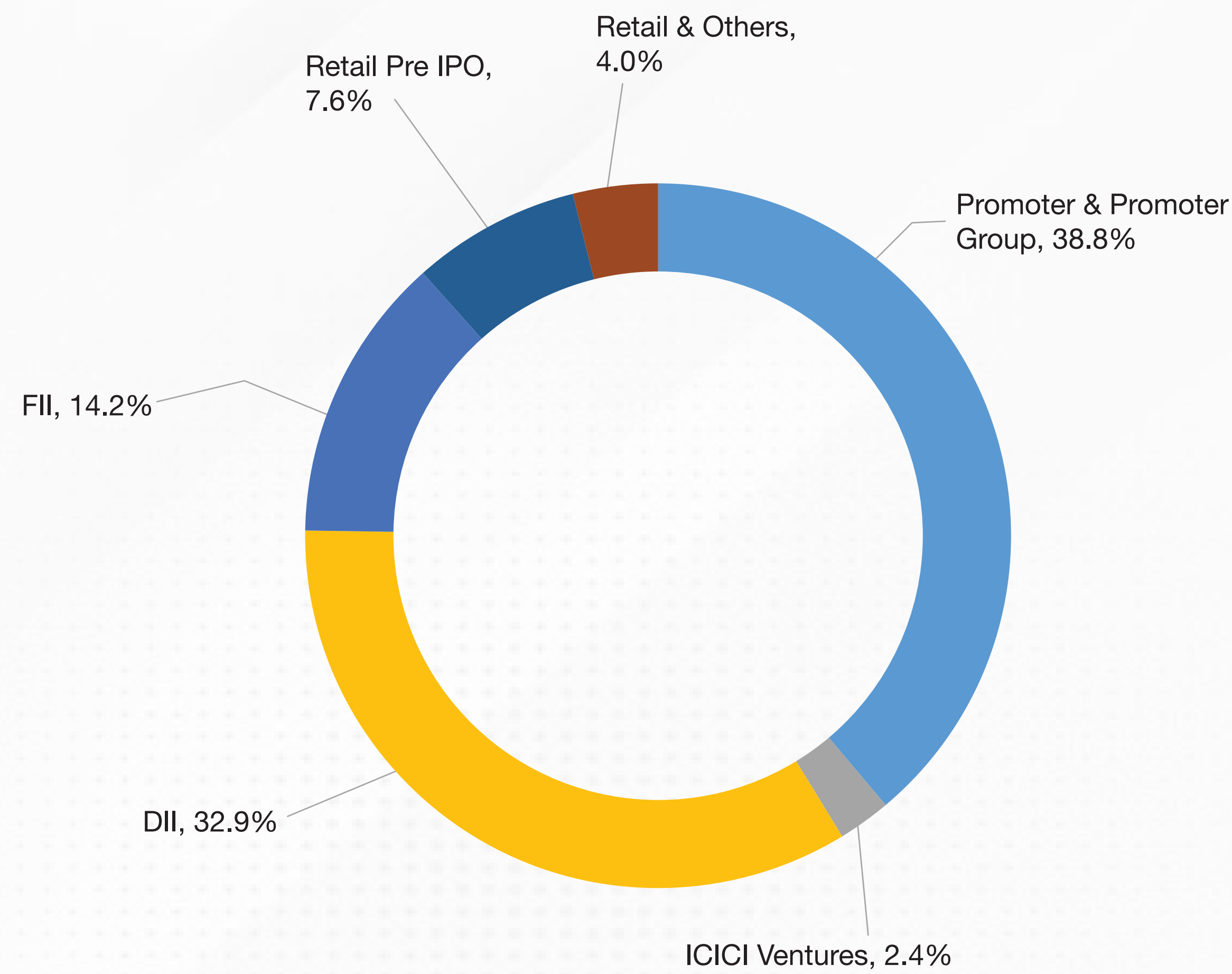


Mr. Ratna Kishore Kaza
Independent Director



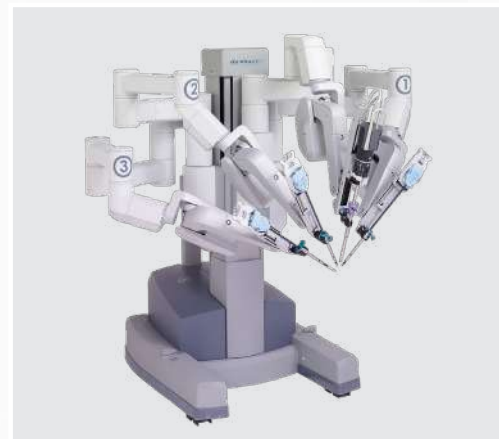Mrs. Y. Prameela Rani
Independent Director

Shareholding Pattern - As on 30th September, 2023



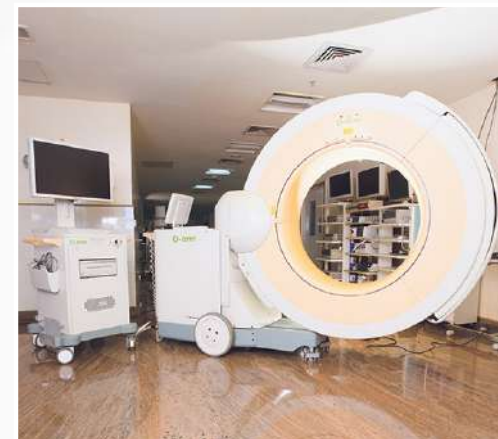Share Holder	No of Shares	Share Holding %	Category
Promoter	3,10,86,304	38.8%	
ICICI Ventures	19,39,393	2.4%	
Sbi MF	51,32,961	6.4%	DII
Axis MF	42,19,311	5.3%	DII
Mirae Asset Mf	36,75,873	4.6%	DII
HDFC MF	26,58,759	3.3%	DII
ICICI MF	22,75,997	2.8%	DII
Nomura	18,51,629	2.3%	FII
Tata Aia Life Insurance	17,19,619	2.1%	DII
Amansa Holdings Private Limited	16,15,302	2.0%	FII
Vanguard Equity Funds	15,91,120	2.0%	FII
Emerald Investments Limited	15,70,000	2.0%	FII

Modern Medical Technology



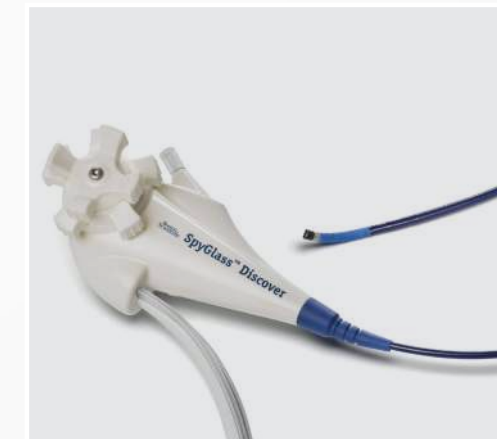4-Arm HD da Vinci Robotic Surgical System

Facilitates complex surgeries that are virtually scar less



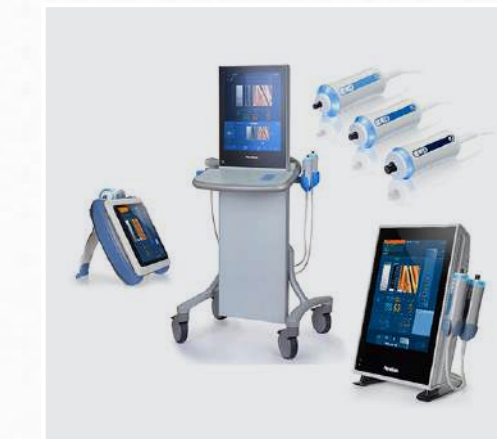O-Arm Scanner

Multi-dimensional surgical imaging platform optimized for use in spine, orthopaedic, and trauma-related surgeries



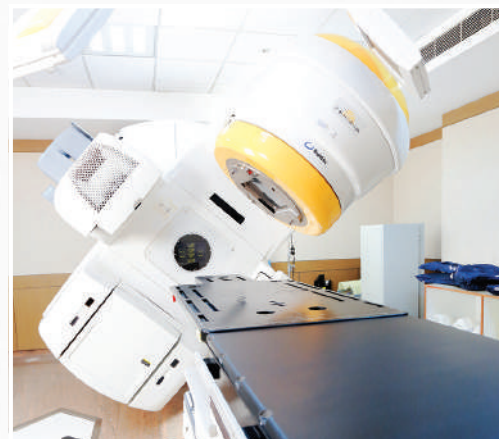Spy Glass

State of the art add on to ERCP that allows doctors to observe patients' biliary duct system and other tiny ducts in the pancreas



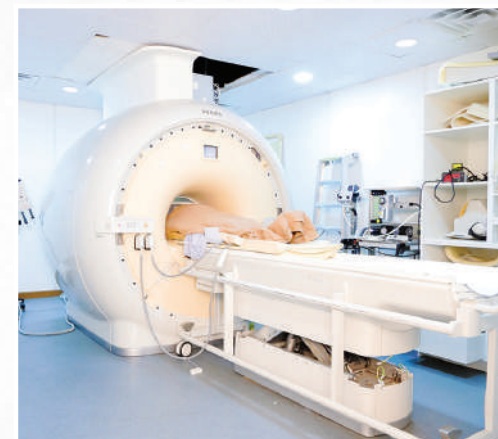Fibroscan

Specialized non-invasive diagnostic ultrasound-based device that measures fibrosis and steatosis caused by different liver diseases



Novalis Tx Linear Accelerator

Machine used in radiosurgery and radiotherapy for treating cancer patients



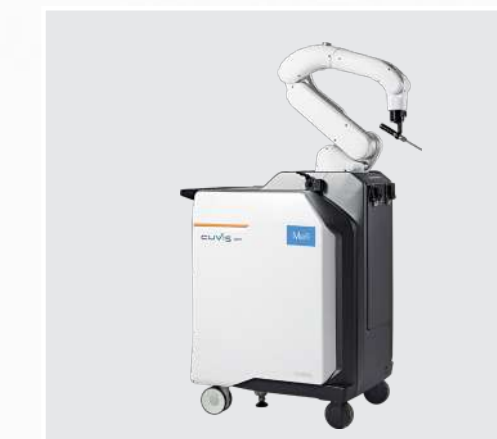3 Tesla MRI

Non-invasive diagnostic imaging technique performing faster scans and gives improved diagnostic sensitivity and specificity



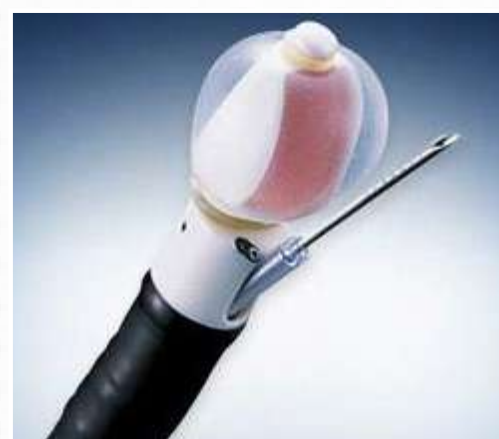Mako Robotic for Knee Replacement

Produces minimal blood loss and a smaller scar. Helps preserve healthy bone and soft tissue. Results in less post-operative pain than manual techniques.



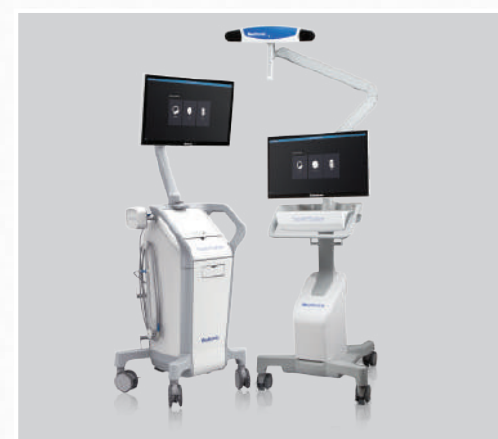Cuvis Ortho Robo

The most advanced surgical equipment capable of 3D pre-planning, virtual surgery and precise cutting to provide accurate and precise surgery results



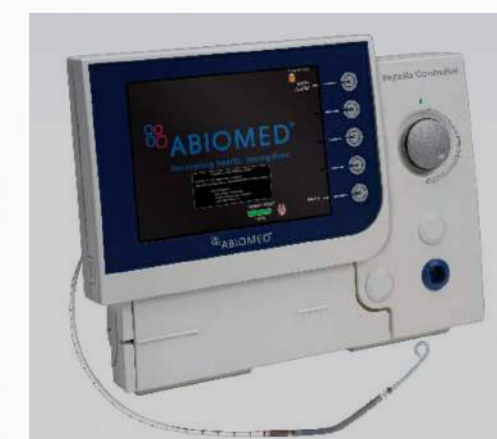EBUS

Used to diagnose lung cancer, infections, and other diseases causing enlarged lymph nodes in the chest



STEALTH STATION S8

Provides the Neuro surgeon to use data intraoperatively for advanced visualization.



IMPELLA

Impella, the world's smallest heart pump, is a percutaneous catheter-based technology that provides hemodynamic support to the heart



EVIS X1 Endoscopy System

The most advanced Endoscopy system helps improving clinical outcomes by providing Endoscopist with innovative and proven tools.

Many Firsts...

- **First in Asia** in to do Trans catheter Tricuspid Valve replacement procedure done in 2018
- **Largest** Joint replacement program in South Asia.
- **One of the largest** neuroscience programs for epilepsy among private hospitals in the country
- **Largest** ECMO program (18 machines) in the country.
- **First hospital in Hyderabad** to use an ECMO machine in 2013.
- **First hospital in Hyderabad** to do a Neonatal ECMO
- **First in India** to do TOF repair using CorMatrix patch for pulmonary valve reconstruction in 2017
- **First in the country** to do Robotic spleen preserving distal pancreatectomy

- **India's first** COVID Double Lung transplant done in 2020
- **India's first** Breathing Lung transplant done in 2021
- **First hospital in South India** to introduce Da Vinci Robotic System
- **The first hospital in Andhra Pradesh** and Telangana to have been Green OT certified in 2016
- **First hospital in India** to perform Arch Repair in Neonates and infants without TCA
- **First Hospital in South India** to do Total Skin Electron Beam Radiation therapy in 2018
- **Number 1 player** in Organ transplantation speciality (Heart, Lung, Liver and Kidney)*

- **Number 1** in Nephrology treatments in Andhra Pradesh*
- **Number 1** in Neurosurgery & Poly trauma treatments in Andhra Pradesh*
- **Number 1** in Cardio related surgeries and treatments programs in Andhra Pradesh *
- **Number 1** in Urology (Genito-Urinary) surgeries performed in Andhra Pradesh*

*As per CRISIL Report 2021

Key Accomplishments



Ranked No. 1 Hospital
by Times of India, Hyderabad



American Accreditation Commission
International (AACI)
Accredited



Pharmacie De Qualite (PDQ)
Certification Overall PDQ Evaluation
Performance Score - 98%
Grading - PLATINUM



'Best Patient Friendly Hospital'
AHPI Health Care Excellence
Award (2017)



'Best Hospital to Work For'
AHPI Global Conclave
Award (2019)



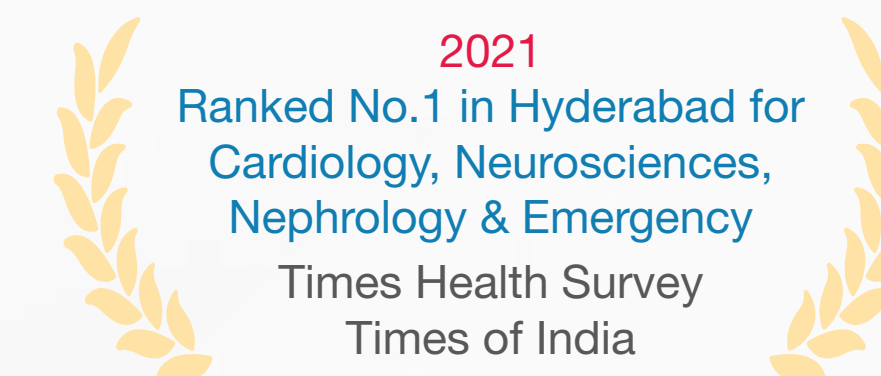
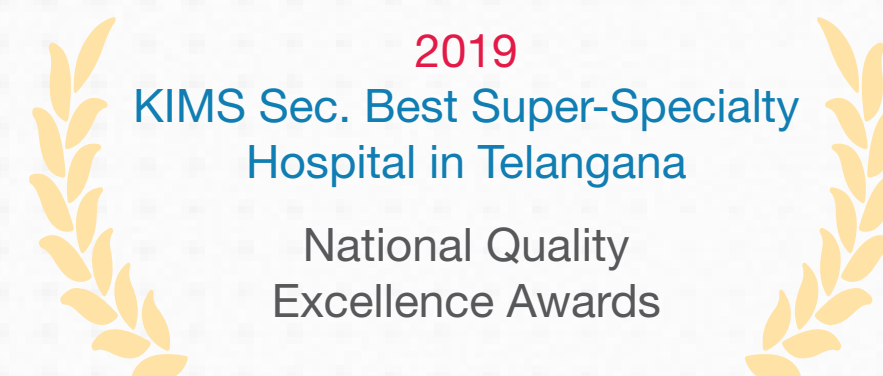2nd Best Hospital in
Hyderabad (2021 & 2022)



20th National Award for
Excellence in Energy Management
Award 2019

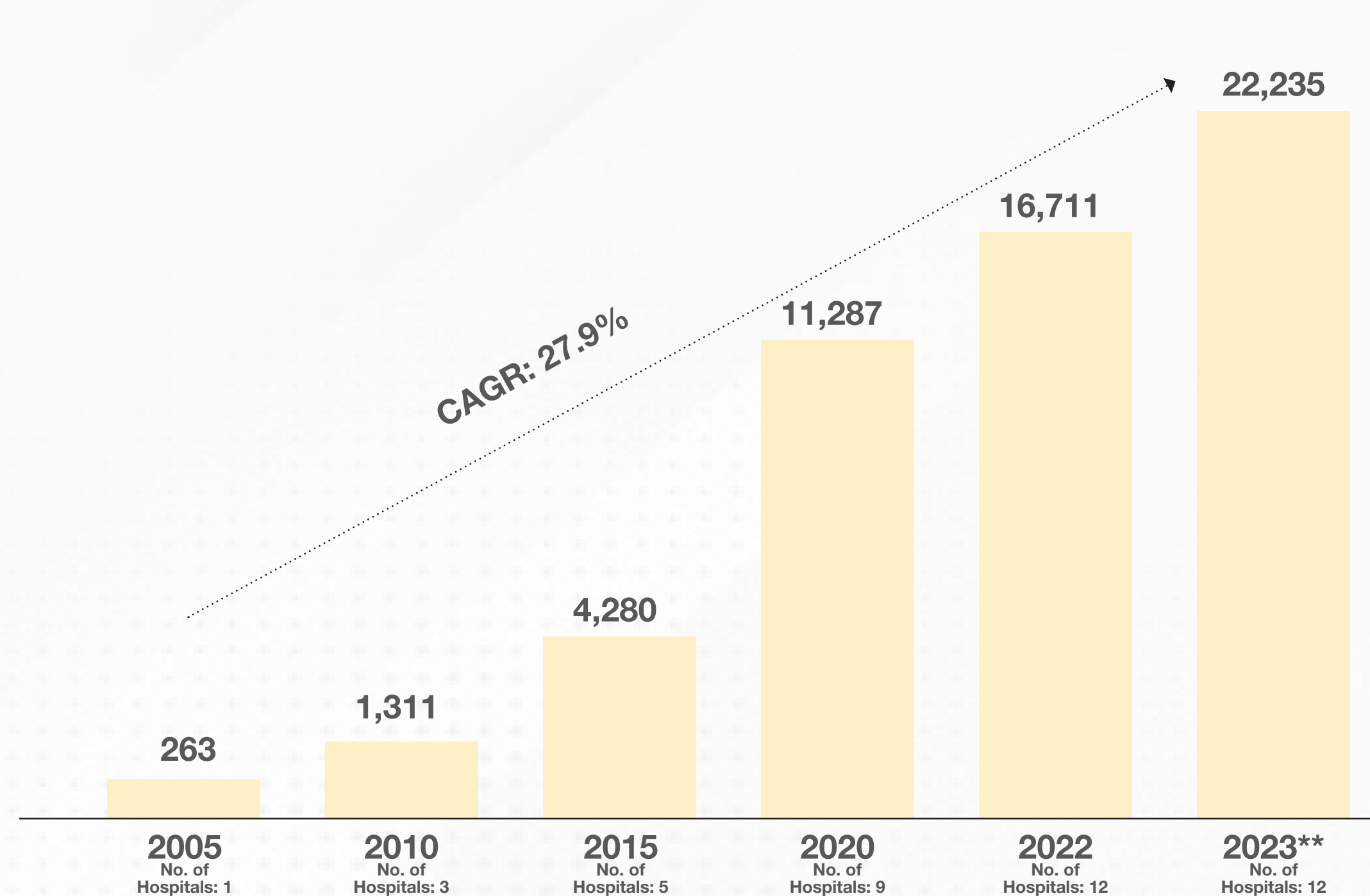


National Quality Excellence
Awards 2019 for Best Super
Specialty Hospital in Telangana

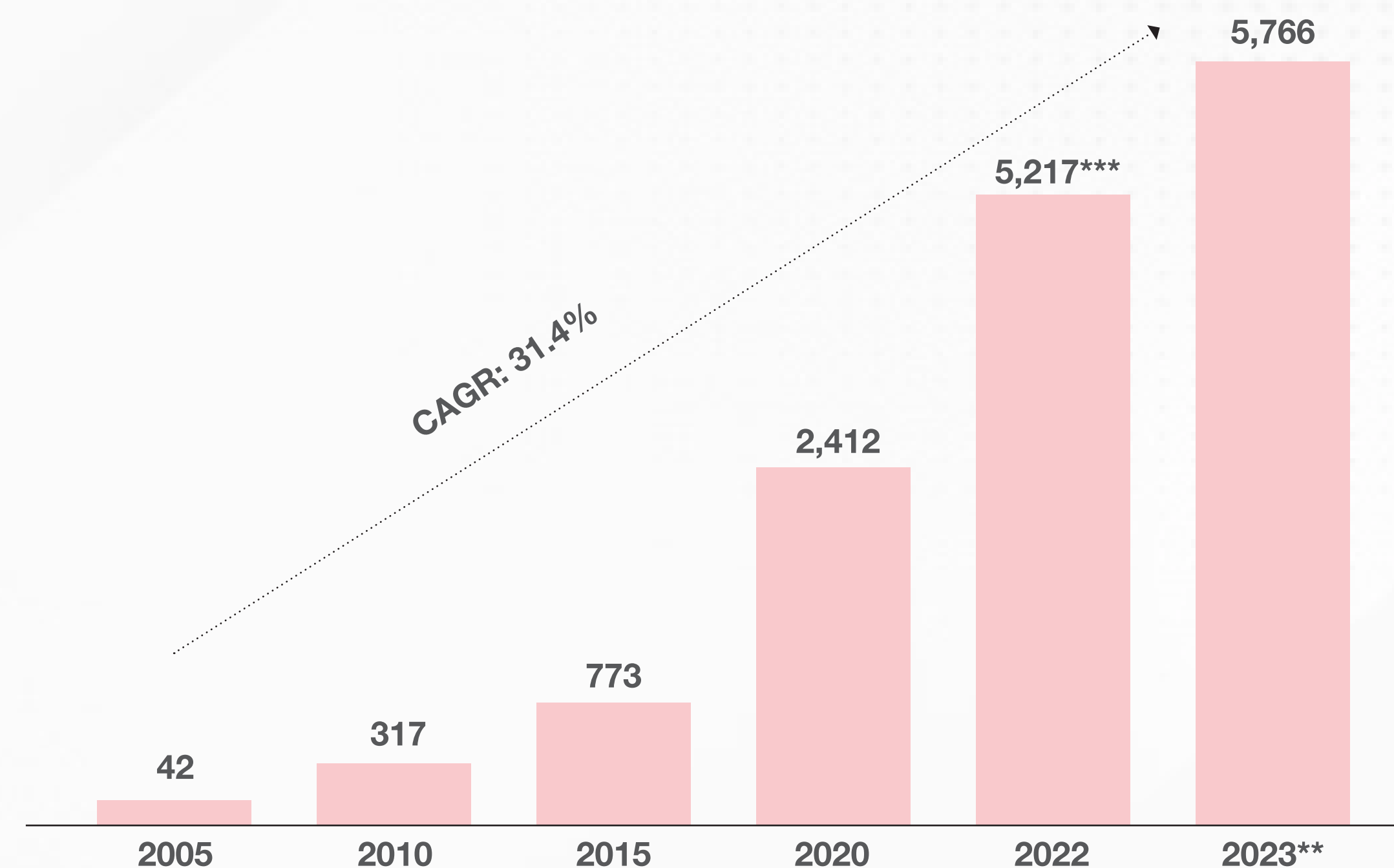


Consistent Performer over 2 decades

(Rupees in Millions)



Total Revenue



***EBITDA**

*EBITDA before IND AS and other income

**Revenue and EBITDA are including 7 month performance (Sep'22 - Mar'23) of the newly acquired unit at Nagpur

***FY22 EBITDA includes share of profit from JV (Sunshine)

Q2 FY24 Updates

FINANCIAL HIGHLIGHTS

Q2 FY 24 Consolidated

- Gross revenue at INR 655 Cr, a growth of 14.3% on a YoY and 7.6% on a QoQ basis.
- Reported Operating EBITDA of INR 180 Cr, an increase of 11.5% YoY and 12.5% QoQ basis.
- Reported EBITDA margin at 27.5% vs. 28.3% in Q2 FY23 and 26.3% in Q1 FY24.
- PAT at INR 101 Cr in Q2 FY24 against INR 91 Cr (before one-offs) and INR 87 Cr in Q2 FY23 and Q1 FY24 respectively.
- Conducted 4.13 lakhs OPD consults in Q2 FY24, up by 10% on YoY and 8% on QoQ basis.
- Bed occupancy in Q2 FY24 at 76.4%, up by 3.8% on YOY and 6% QoQ basis.
- ARPOB at INR 31,140 in Q2 FY24, 6.5% growth YOY and marginal decline of 1.8% on QoQ basis.
- Cash and Cash Equivalents at INR 104 Cr in Q2 FY24. Net Debt to Equity ratio at 0.26
- Consolidated Key Financials figures are as follows (Rs in Mn) :

Particulars	Consolidated - FY24 Q2 Results				
	Q2 FY 24	Q1 FY 24	Q2 FY 23	QoQ	YoY
Total Income	6,553.6	6,091.4	5,732.8		
Less : Other Income	28.9	31.1	92.0		
Revenue from Operations	6,524.8	6,060.3	5,640.7	7.7%	15.7%
PBT*	1,386.3	1,185.8	1,226.4	16.9%	13.0%
Add : Interest	89.1	93.3	78.8		
Add : Depreciation	326.1	322.6	311.2		
Reported EBITDA (Including other income) as per Financials	1,801.6	1,601.8	1,616.4	12.5%	11.5%
Less : Other Income	28.9	31.1	92.0		
Less : INDAS	49.9	23.1	77.3		
EBITDA Pre INDAS & Other Income	1,722.8	1,547.5	1,447.1	11.3%	19.1%
EBITDA % to Revenue from Operations	26.4%	25.5%	25.7%		

*PBT are excluding items of:

- 1) Fair value gain on aquisition of control of Rs. 148.3 Mn in Q2 FY23
- 2) Share of loss of associate of Rs.0.22mn in Q2 FY24

FINANCIAL HIGHLIGHTS

Q2 FY 24 Consolidated

- Consolidated Revenue grew by 14.3% on a YoY and 7.6% on a QoQ basis to INR 655 Cr
- Consolidated EBITDA (Pre-INDAS and excluding Other Income) grew by 19.1% on a YoY and 11.3% on a QoQ basis to INR 172 Cr
- Consolidated EBITDA (Pre-INDAS and excluding Other Income) Margin stands at 26.4%, showing an increase of 0.9% from previous quarter.
- Consolidated PAT increased by 11.0% (before one offs) on a YoY and by 16.9% on a QoQ basis to INR 101 Cr.
- Consolidated EPS declined by 5.3% on a YoY and increased by 13.9% on a QoQ basis to INR 11.5

OPERATIONAL HIGHLIGHTS

Q2 FY 24 Consolidated

- Sunshine and Nagpur units integrating well as per KIMS practices.
- IVF Started at Nagpur Unit
- There was consistent growth on IP volumes and OP volumes on QoQ as well as YoY basis.

Details in the table below.

Particulars	FY24 Q2 Results				
	Q2 FY 24	Q1 FY 24	Q2 FY 23	QoQ	YoY
IP Volumes	51,115	46,205	46,616	10.6%	9.7%
OP Volumes	4,13,020	3,82,387	3,75,188	8.0%	10.1%
ARPOB (Rs)	31,140	31,697	29,237	-1.8%	6.5%
ARPP (Rs)	1,27,959	1,31,363	1,21,302	-2.6%	5.5%

PROJECT STATUS

- KIMS Sunshine Secunderabad Hospital will be completely shifted to a new state-of-the-art facility by November'23
- Visakhapatnam single speciality (Gastro Sciences) unit is fully operational.
- On the digital side, SAP has been successfully implemented and gone live at a few of our units and is expected to be fully implemented across all units by the end of FY 24.

DIGITAL INITIATIVES

During the last quarter, KIMS continued its digitization journey with a goal of having 100% paperless business processes in all its operational, clinical and finance verticals. As part of this journey, last quarter we have either initiated or delivered the following programs:

- Delivered OT Module
- Delivered Corp OPD Enhancement and went live in Secunderabad
- Enabled Tele-Radiology support for Nagpur, Gachibowli and Paradise units
- QMS and FC enhancements delivered
- Introduced Qure.AI and RapidAI integration as part of Clinical Excellence
- Introduced LifeSigns and Dozee as Wireless (No Touch) Patient Vital Monitoring solutions
- Delivered ER Module
- Delivered Dialysis Module
- Integrated ClaimTherapist
- Delivered MultiSite support for Lab Orders
- Delivered IP Patient Service Portal (KIMS Suvidha)

ESG INITIATIVES

KIMS, Secunderabad has partnered up with Smart Joules Pvt Ltd (SJPL) a prominent Energy Services Company (ESCO) in 2018. A new and innovative model known as JoulePAYS was executed wherein, KIMS makes Zero Capital investment to implement various Energy Conservation Measures (ECMs) across the hospital and gets a guaranteed energy savings of minimum 10% annually over the baseline energy consumption. Company is also expecting to sign up Captive Solar Investment in Nagpur SPV as part of non renewal energy source, resulting in reduction in power cost. On the same lines company is also evaluating other locations.

For the period Jul 2023 – Sep 2023:

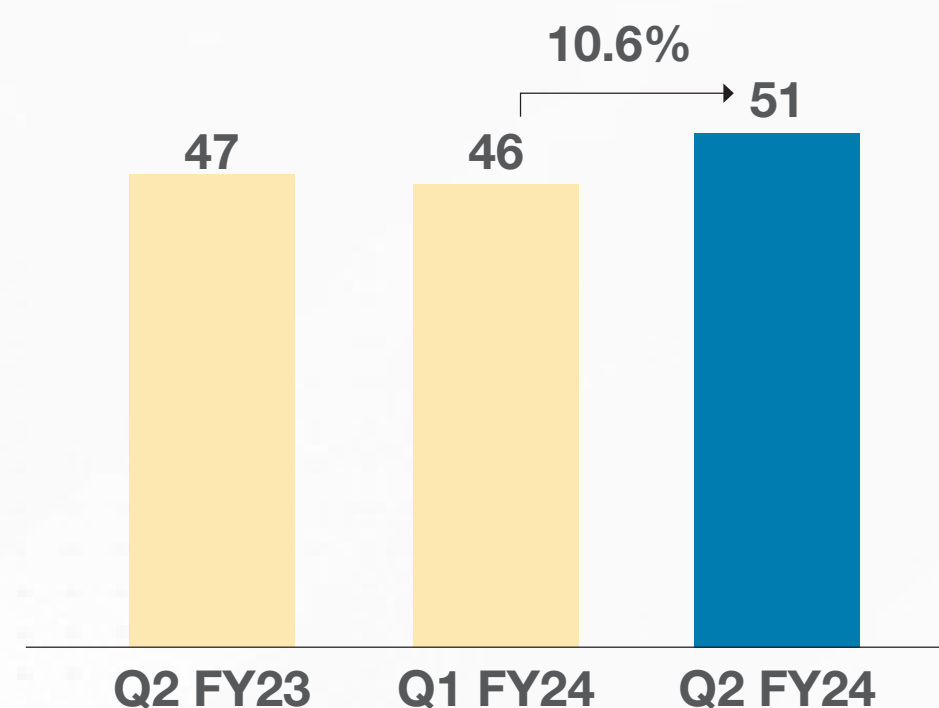
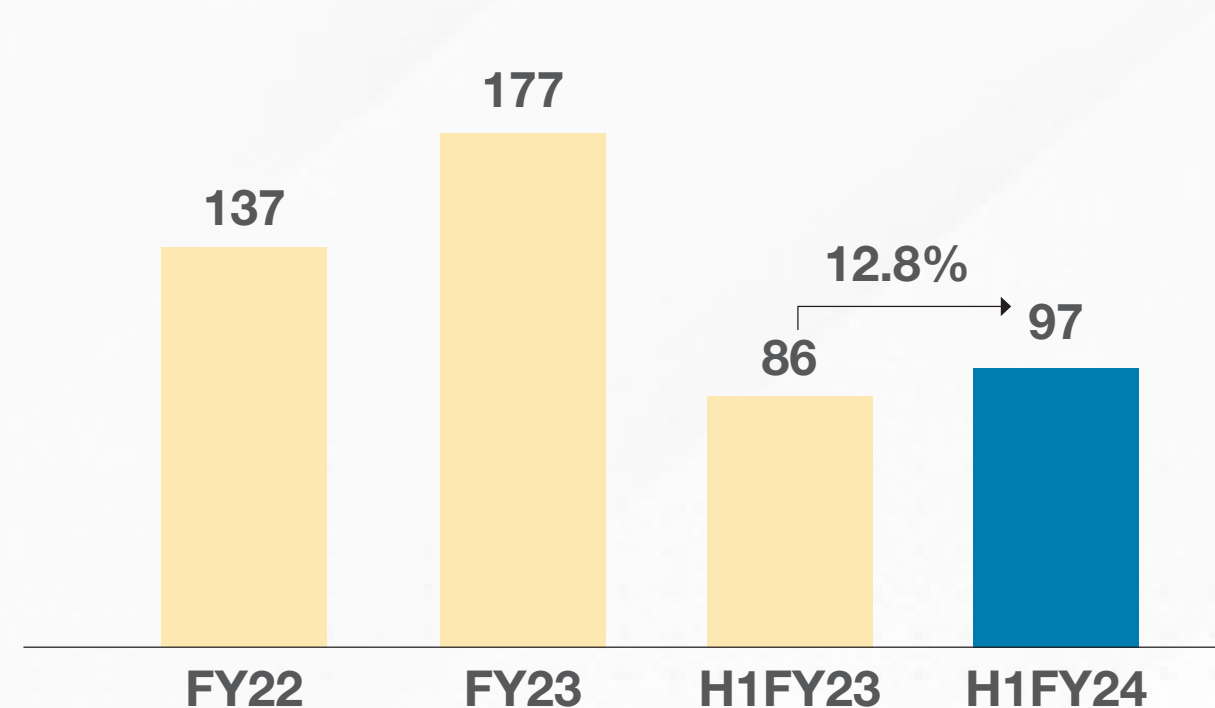
- 19.6% of total energy consumption saved
- INR 66.92 lakhs of total energy cost saving achieved
- 445 tonnes CO2 saved

In real life translation, the above translates to approximately the following:

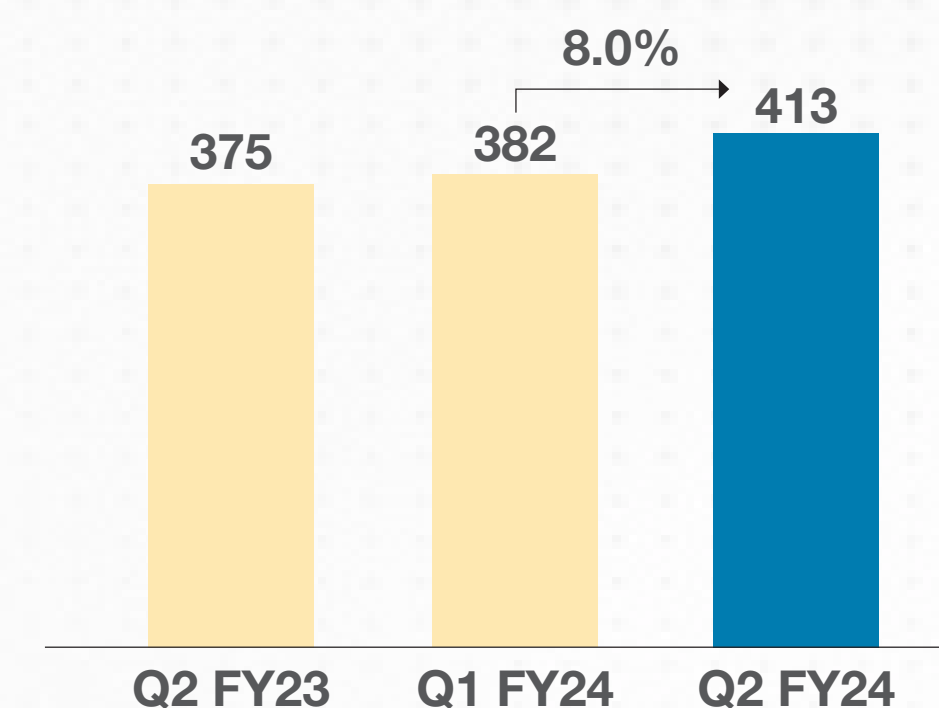
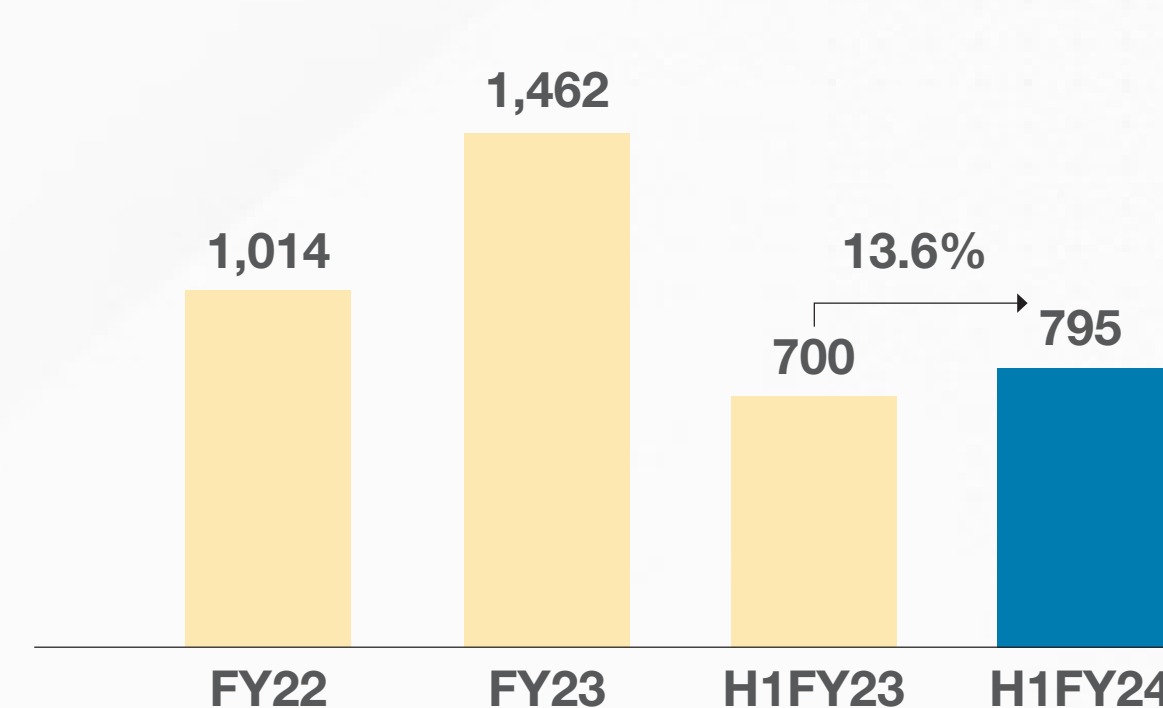
- 8,451 households getting electricity
- 17.99 Lakhs Kms less driven
- 18,240 trees planted

Group Operating Performance - 1/3

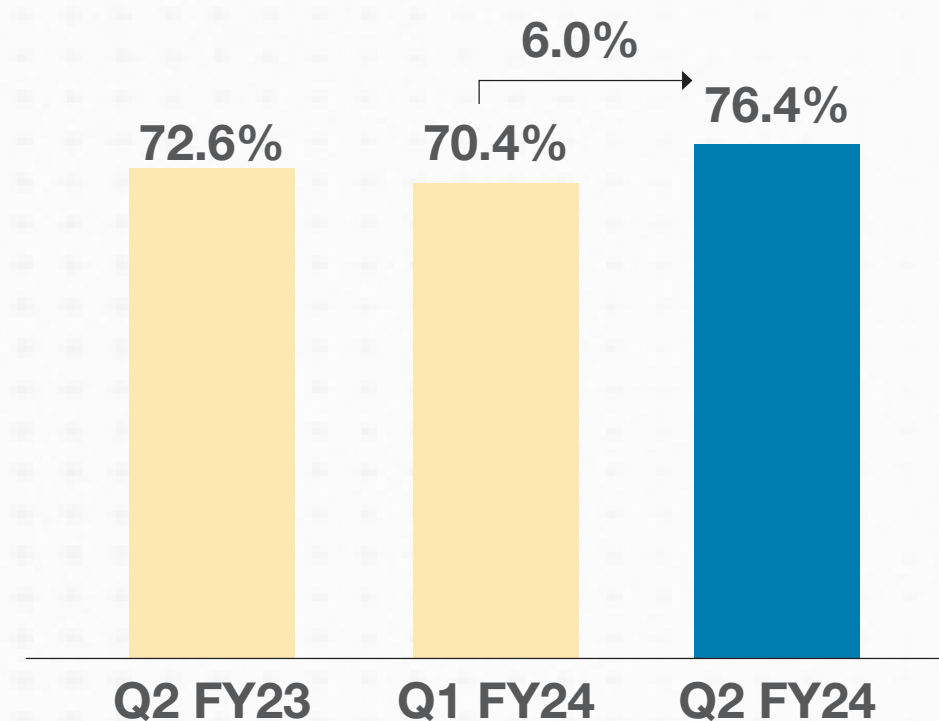
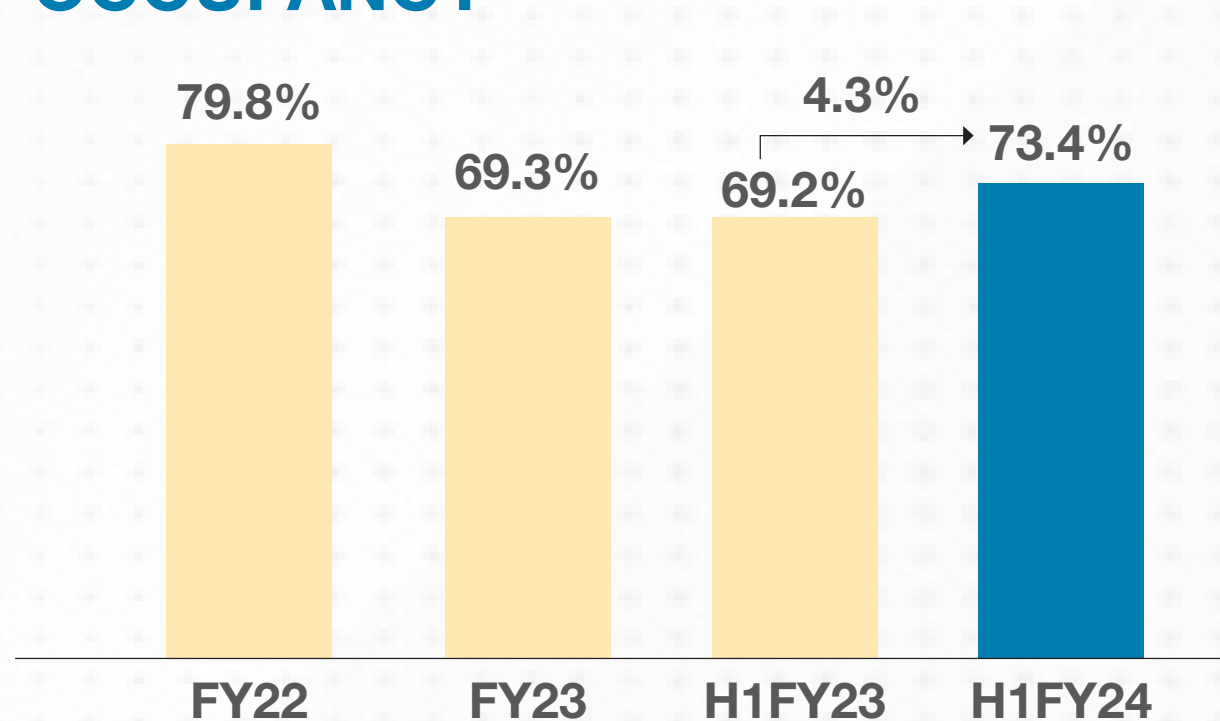
IP VOLUME ('000)



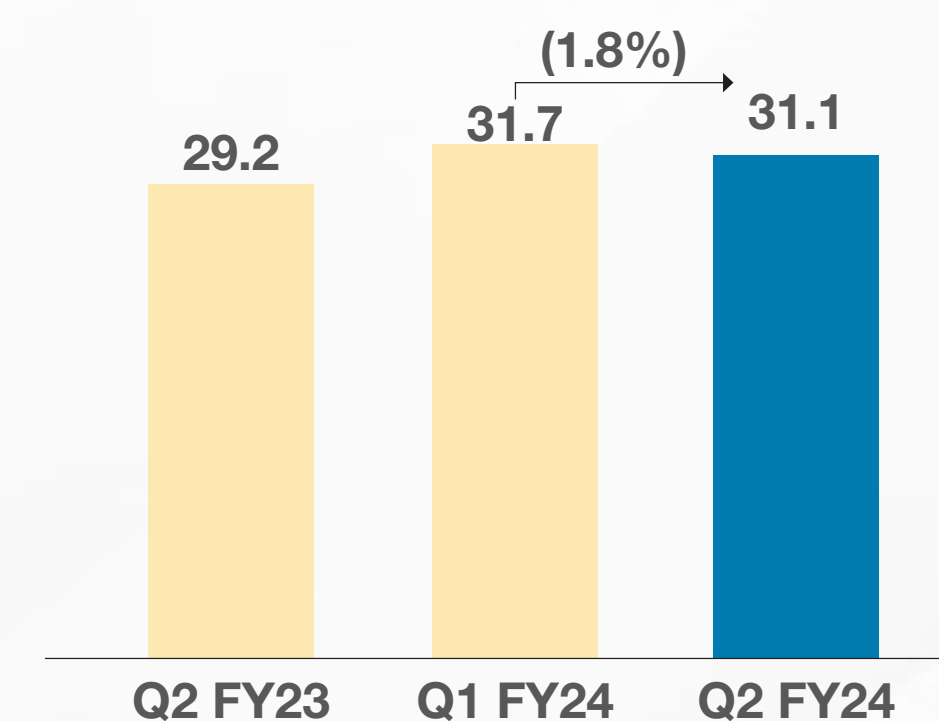
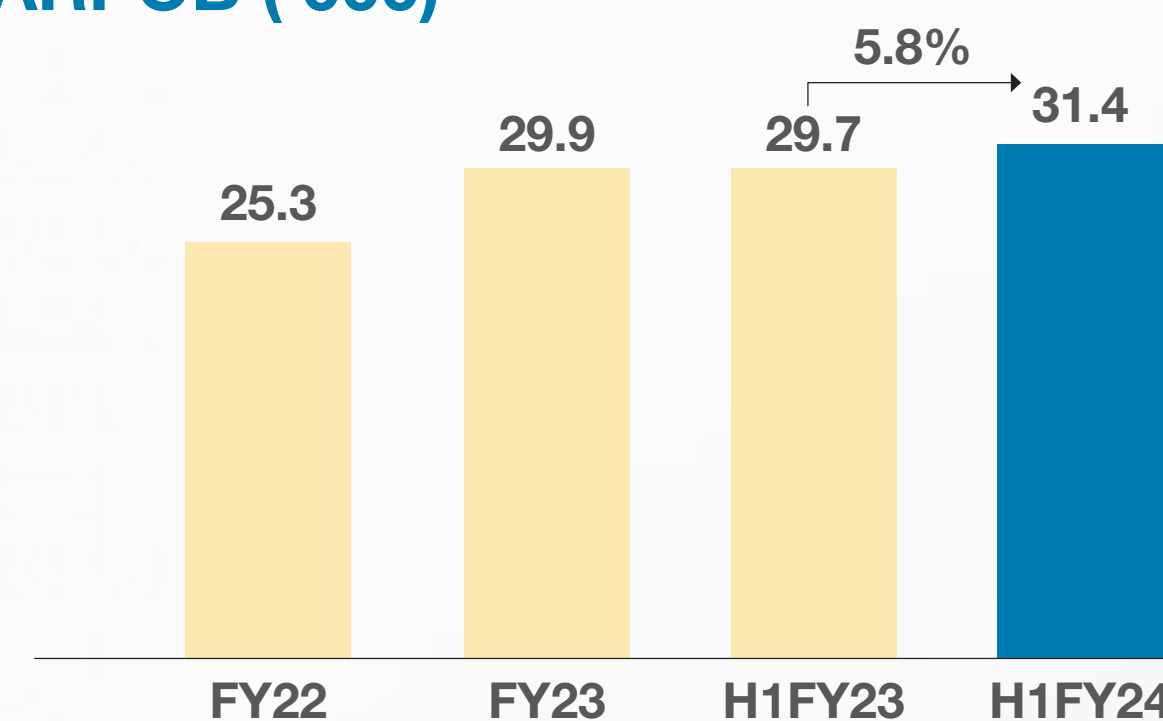
OP VOLUME ('000)



OCCUPANCY*



ARPOB ('000)

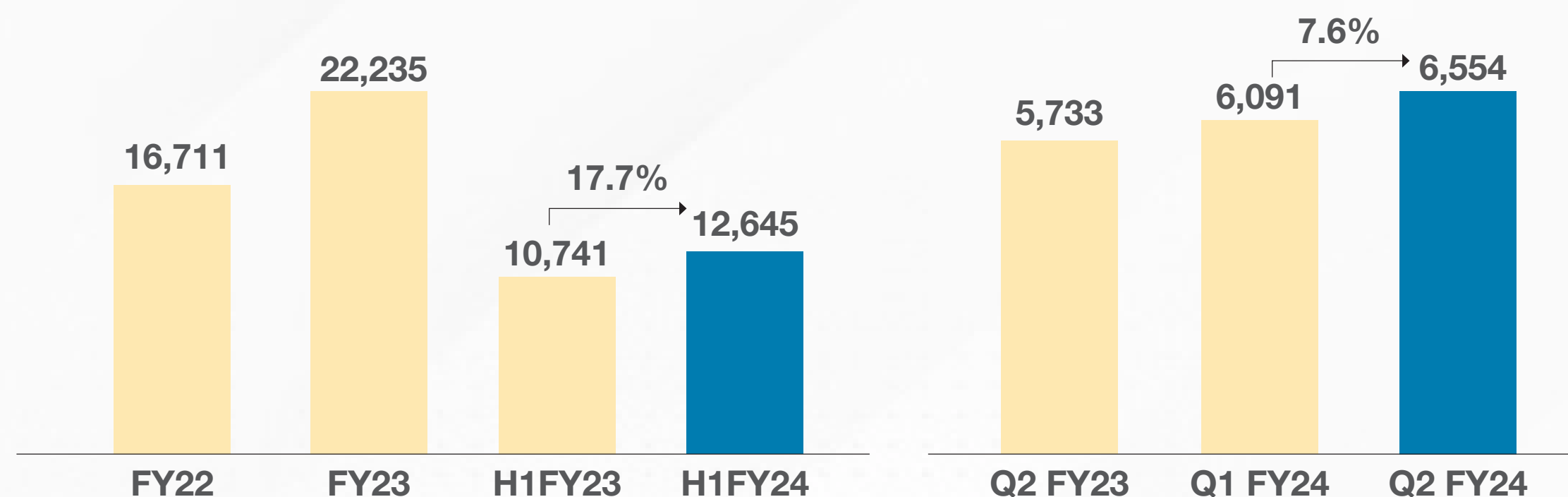


*Occupancy % based on operational Census Beds

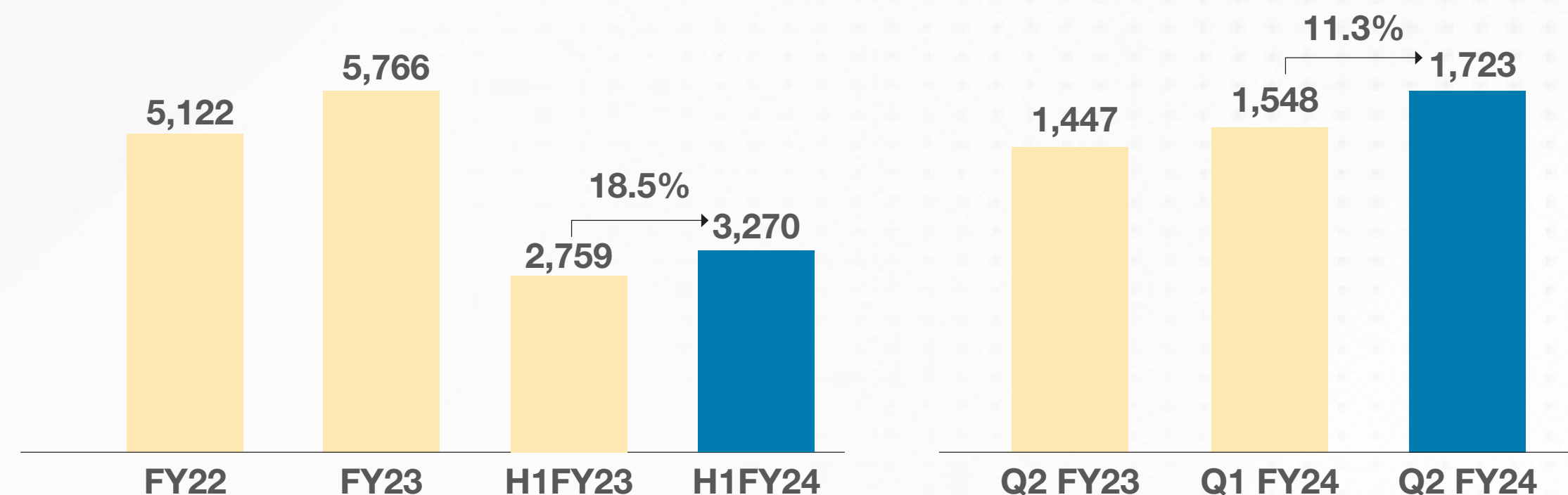
Group Operating Performance - 2/3

(Rupees in Millions)

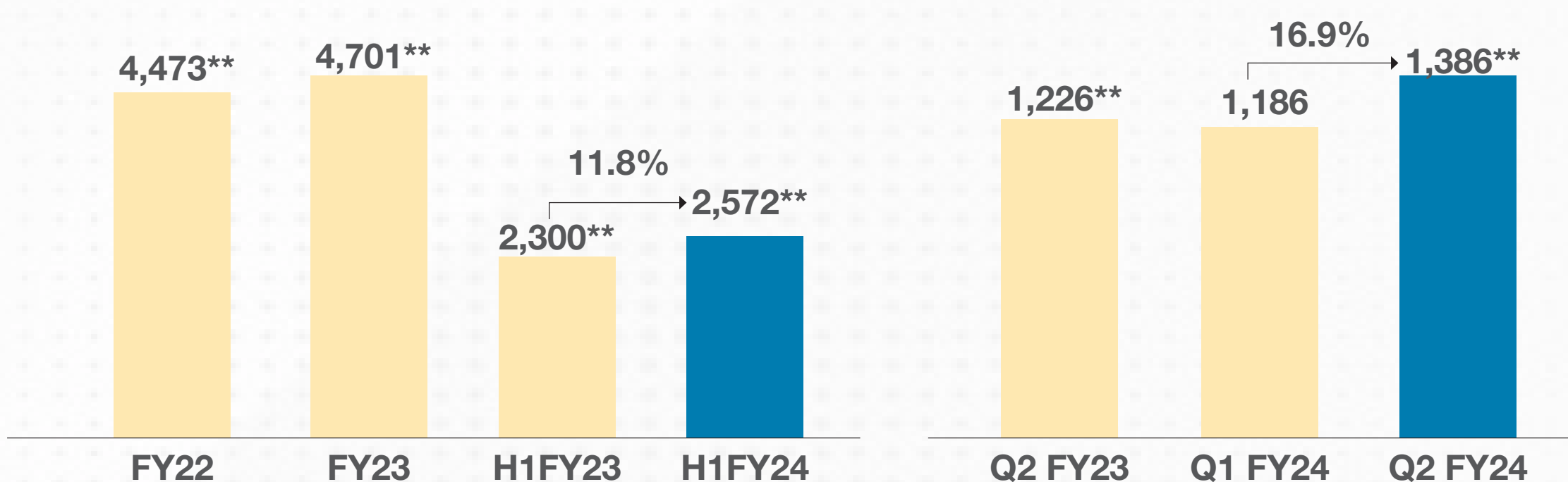
TOTAL REVENUE



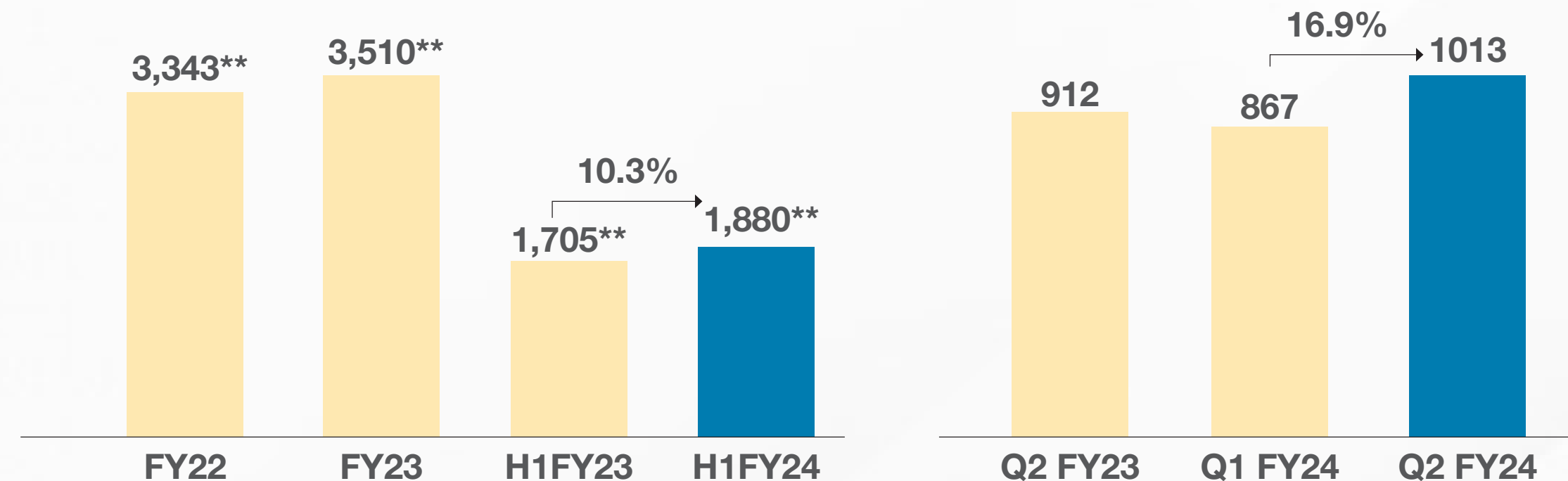
EBITDA*



PBT



PAT



*EBITDA before IND AS and other income

**PBT and PAT are excluding items of:

- 1) Associates share of profit of Rs. 95.1 Mn in FY22
- 2) Fair value gain on aquisition of control of Rs. 148.3 Mn in Q2 FY23
- 3) Share of loss of associate of Rs.0.22mn in Q2 FY24

Group Operating Performance - 3/3

Particulars	FY22	FY23	H1 FY23	H1 FY24	Q2 FY23	Q1 FY24	Q2 FY24
Bed Capacity	3,064	3,940	4,015	3,975	4,015	3,975	3,975
Operational Beds	2,590	3,468	3,543	3,503	3,543	3,503	3,503
Census Beds	2,246	2,960	3,026	2,989	3,026	2,989	2,989
Non Census Beds	344	508	517	514	517	514	514
Occupied Beds	1,793	2,071	2,108	2,194	2,223	2,104	2,283
Occupancy [#]	79.8%	69.3%	69.2%	73.4%	72.6%	70.4%	76.4%
IP volume	1,36,731	1,77,181	86,289	97,320	46,616	46,205	51,115
OP volume	10,13,759	14,62,439	699,985	7,95,407	3,75,188	3,82,387	4,13,020
ARPOB (Rs.)	25,323	29,946	29,640	31,406	29,237	31,697	31,140
ARPP (Rs.)	1,21,232	1,24,187	123,067	1,29,575	1,21,302	1,31,363	1,27,959
ALOS	4.79	4.15	4.15	4.13	4.15	4.14	4.11
Total Revenue (Rs.in Mn)	16,711	22,235	10,741	12,645	5,733	6,091	6,554
EBITDA* (Rs.in Mn)	5,122	5,766	2,759	3,270	1,447	1,548	1,723
EBITDA % to Total Revenue	30.7%	25.9%	25.7%	25.9%	25.2%	25.4%	26.3%
PBT** (Rs. in Mn)	4,473	4,701	2,300	2,572	1,226	1,186	1,386
PAT** (Rs. in Mn)	3,343	3,510	1,705	1,880	912	867	1,013

*EBITDA before IND AS and other income

**PBT and PAT are excluding items of:

- 1) Associates share of profit of Rs. 95.1 Mn in FY22
- 2) Fair value gain on aquisition of control of Rs. 148.3 Mn in Q2 FY23
- 3) Share of loss of associate of Rs.0.22mn in Q2 FY24

[#]Occupancy % based on operational Census Beds

Comparison of Telangana and Andhra Pradesh Hospitals - 1/2

Particulars	Telangana (KIMS)						Andhra Pradesh (KIMS)					
	FY22	FY23	Q2 FY23	Q1 FY24	Q2 FY24	H1 FY24	FY22	FY23	Q2 FY23	Q1 FY24	Q2 FY24	H1 FY24
Bed Capacity	1,200	1,200	1,200	1,200	1,200	1,200	1,864	1,879	1,879	1,914	1,914	1,914
Operational Beds	1,035	1,085	1,085	1,085	1,085	1,085	1,555	1,606	1,606	1,641	1,641	1,641
Census Beds	856	906	906	906	906	906	1,390	1,441	1,441	1,470	1,470	1,470
Non Census Beds	179	179	179	179	179	179	165	165	165	171	171	171
Occupied Beds	642	644	668	644	667	656	1,151	1,107	1,169	1,155	1,238	1,196
Occupancy	75.0%	71.5%	73.8%	71.0%	73.7%	72.4%	82.8%	77.5%	81.1%	78.5%	84.2%	81.4%
IP volume	53,567	59,077	15,959	15,071	16,038	31,109	83,164	88,092	23,079	22,720	24,939	47,659
OP volume	4,35,663	5,60,936	1,43,885	1,42,270	1,52,626	2,94,896	5,78,096	6,30,178	1,67,169	1,59,096	1,66,836	3,25,932
ARPOB (Rs.)	46,745	46,601	46,310	49,127	50,268	49,711	13,376	14,687	14,120	15,747	15,491	15,614
ARPP (Rs.)	2,04,519	1,85,540	1,78,435	1,90,930	1,92,449	1,91,713	67,585	67,339	65,816	72,823	70,741	71,734
ALOS	4.38	3.98	3.85	3.89	3.83	3.86	5.05	4.58	4.66	4.62	4.57	4.59
Total Revenue (Rs. in Mn)	11,066	11,095	2,905	2,892	3,092	5,984	5,645	5,952	1,523	1,658	1,768	3,426
EBITDA* (Rs. in Mn)	3,987	3,483	844	884	941	1,825	1,230	1,425	377	372	437	809
EBITDA % to Total revenue	36.0%	31.4%	29.1%	30.6%	30.4%	30.5%	21.8%	24.6%	24.7%	22.4%	24.7%	23.6%

*EBITDA before IND AS and other income

Intercompany eliminations and dormant units are adjusted in Telangana

1) Telangana - Secunderabad and Kondapur

2) AP Assets - Nellore, Rajahmundry, Srikakulam, Ongole, Visakhapatnam, Anantapur and Kurnool

Comparison of Sunshine, Nagpur & Group - 2/2

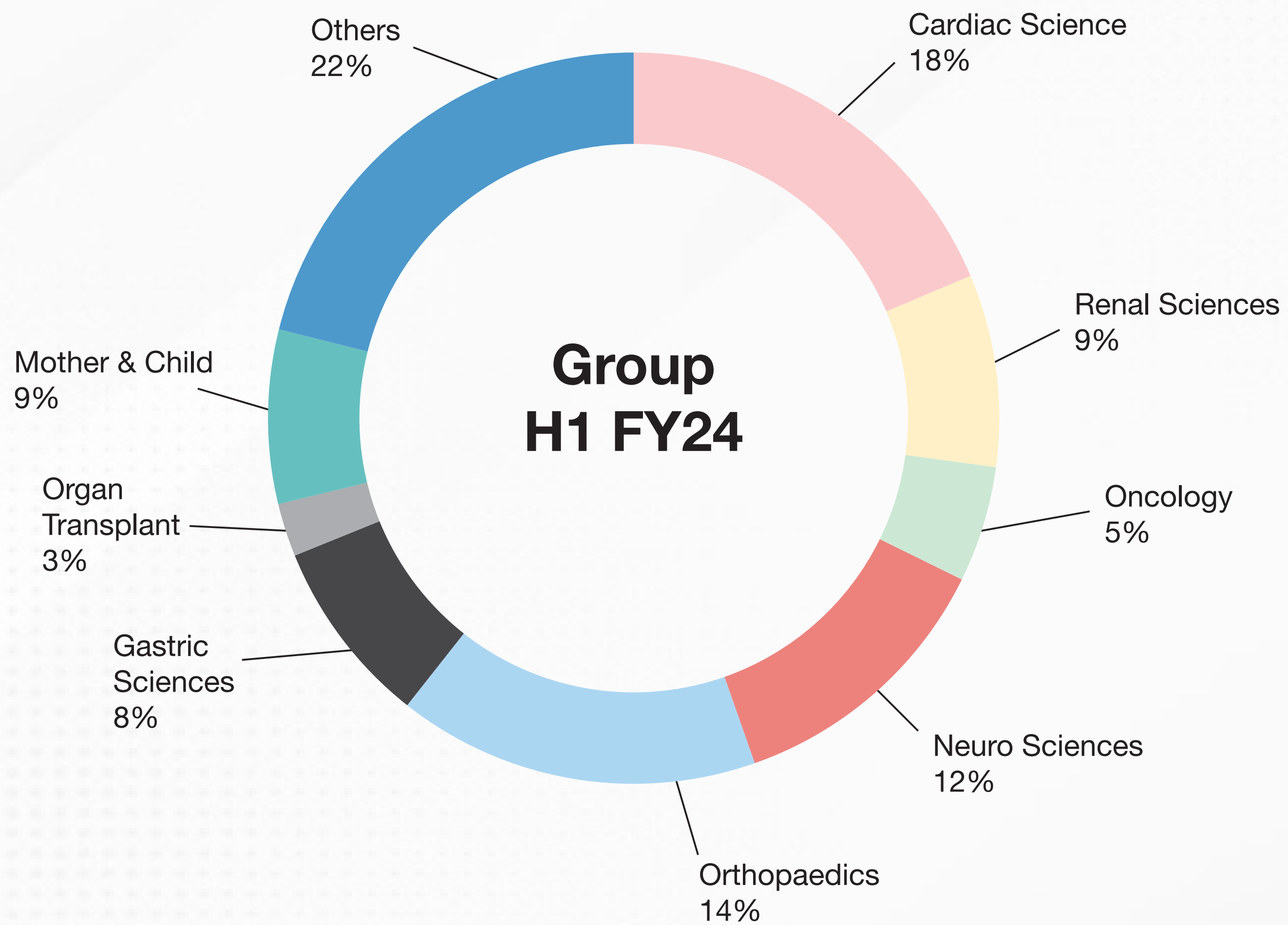
Particulars	Sunshine					Nagpur					Group					
	FY23	Q2 FY23	Q1 FY24	Q2 FY24	H1 FY24	FY23**	Q2 FY23**	Q1 FY24	Q2 FY24	H1 FY24	FY22	FY23	Q2 FY23	Q1 FY24	Q2 FY24	H1 FY24
Bed Capacity	527	602	527	527	527	334	334	334	334	334	3,064	3,940	4,015	3,975	3,975	3,975
Operational Beds	527	602	527	527	527	250	250	250	250	250	2,590	3,468	3,543	3,503	3,503	3,503
Census Beds	418	484	418	418	418	195	195	195	195	195	2,246	2,960	3,026	2,989	2,989	2,989
Non Census Beds	109	118	109	109	109	55	55	55	55	55	344	508	517	514	514	514
Occupied Beds	182	206	184	221	202	137	179	122	157	140	1,793	2,071	2,223	2,104	2,283	2,194
Occupancy	39.5%	42.6%	43.9%	52.8%	48.4%	70.4%	92.0%	62.7%	80.4%	71.6%	79.8%	69.3%	72.6%	70.4%	76.4%	73.4%
IP volume	20,788	5,901	5,192	6,066	11,258	9,224	1,677	3,222	4,072	7,294	1,36,731	1,77,181	46,616	46,205	51,115	97,320
OP volume	2,05,697	54,845	50,083	57,043	1,07,126	65,628	9,289	30,938	36,515	67,453	10,13,759	14,62,439	3,75,188	3,82,387	4,13,020	7,95,407
ARPOB (Rs.)	63,844	60,419	68,584	60,765	64,294	29,597	26,489	35,148	31,535	33,108	25,323	29,946	29,237	31,697	31,140	31,406
ARPP (Rs.)	2,04,371	1,94,104	2,20,812	2,03,576	2,11,525	93,448	85,035	1,21,388	1,11,745	1,16,005	1,21,232	1,24,187	1,21,302	1,31,363	1,27,959	1,29,575
ALOS	3.20	3.21	3.22	3.35	3.29	3.16	3.21	3.45	3.54	3.50	4.79	4.15	4.15	4.14	4.11	4.13
Total Revenue (Rs. in Mn)	4,304	1,162	1,148	1,240	2,388	884	143	392	455	847	16,711	22,235	5,733	6,091	6,554	12,645
EBITDA* (Rs. in Mn)	815	212	266	288	554	44	14	25	57	83	5,122	5,766	1,447	1,548	1,723	3,270
EBITDA % to Total Revenue	18.9%	18.2%	23.2%	23.2%	23.2%	5.0%	9.7%	6.5%	12.6%	9.8%	31.2%	26.2%	25.2%	25.4%	26.3%	25.9%

*EBITDA before IND AS and other income

1) Sunshine - All 3 units (Karimnagar Unit sold in November 22)

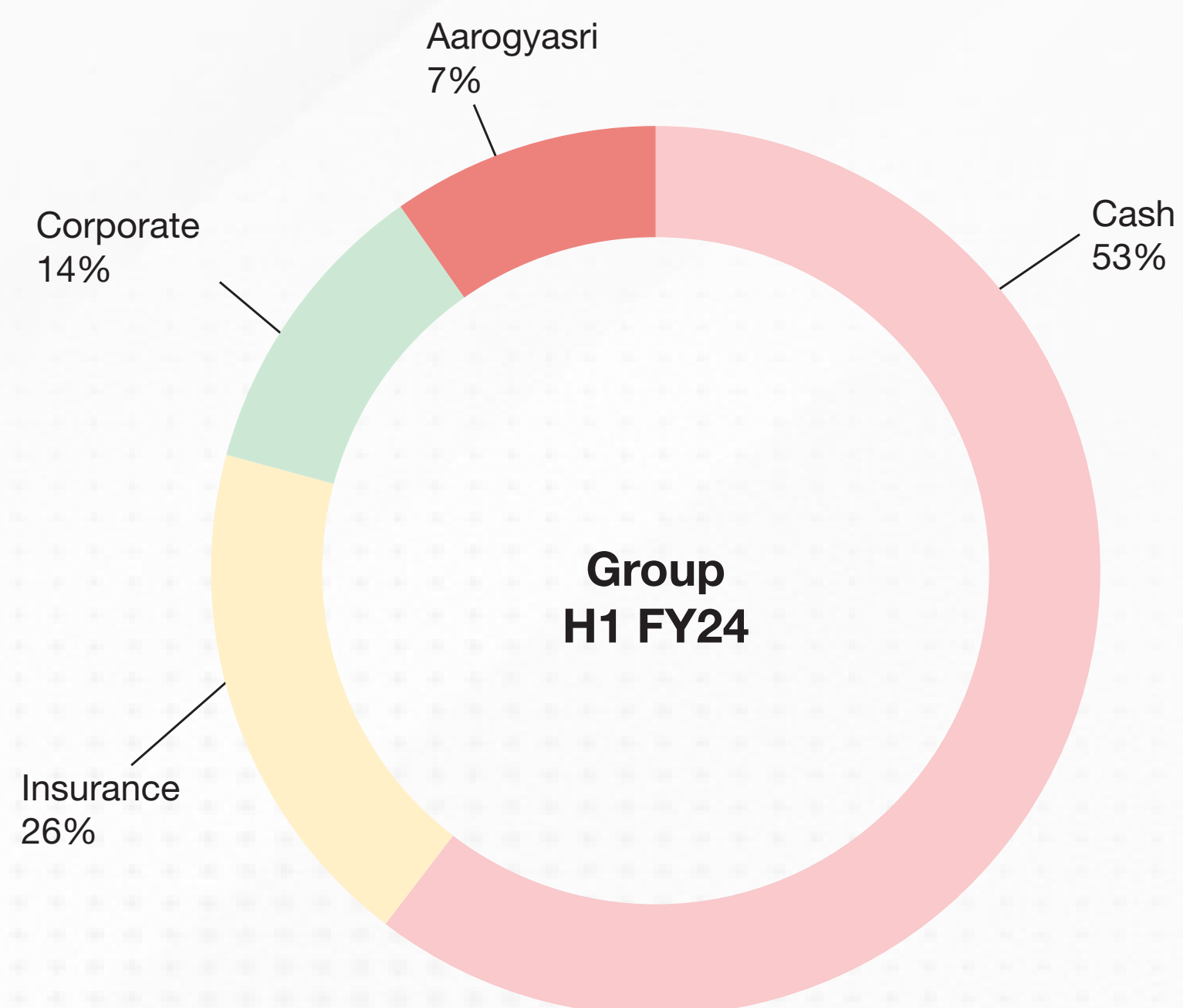
2) **Nagpur - Started operations from September 2022

Speciality Mix

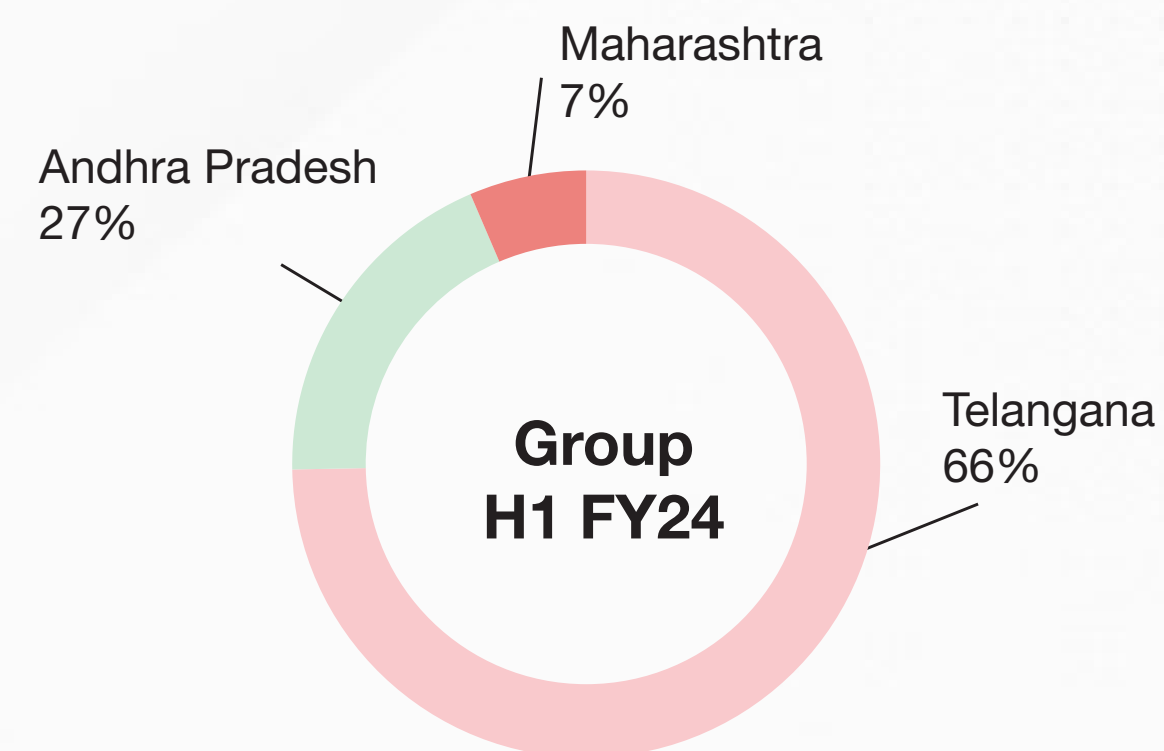


Payor & Cluster Profile

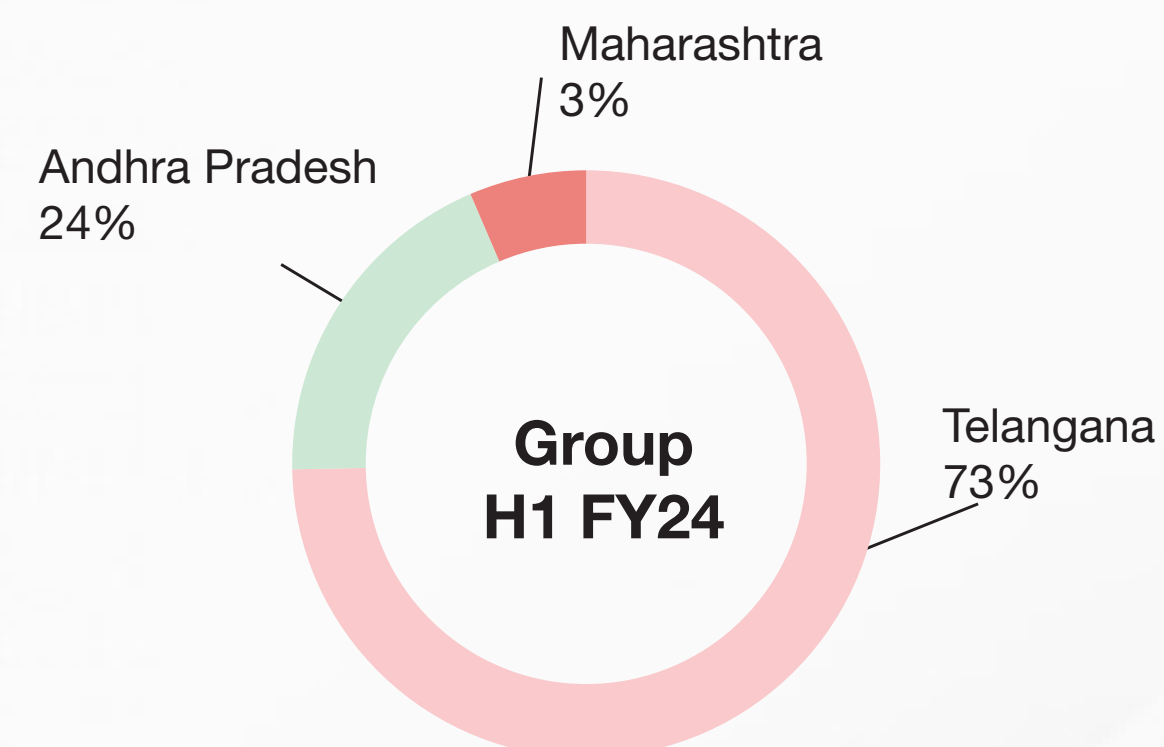
PAYOR MIX



CLUSTER TOTAL REVENUE



CLUSTER EBITDA*



*EBITDA before IND AS and other income

1) Telangana - Secunderabad, Kondapur & Sunshine 2 hospitals

2) AP - Nellore, Rajahmundry, Srikakulam, Ongole, Visakhapatnam, Anantapur and Kurnool

3) Maharashtra - Nagpur

65-year-old woman gets a stent in spine

CITY BUREAU

Hyderabad

The surgeons at Krishna Institute of Medical Sciences (KIMS), Kondapur, on Tuesday reported a vertebral body stenting (VBS) on a 65-year-old woman patient, who suffered a fall.

The VBS, a minimally invasive technique where a metal stent is used to stabilise fractures just like a cardiac stent, was performed by Dr Krishna Chaitanya, senior spine surgeon from the hospital, a press release said.

After the fall, the patient

14-month-old baby's organ donated!

THE KIDNEY WAS TRANSPLANTED TO A 58-YEAR-OLD WOMAN

RARE SURGERY AT KIMS HOSPITAL, SECUNDERABAD

DECCAN NEWS SERVICE
HYDERABAD

Organ donation usually refers only to adults. However, a 14-month-old baby was brain-dead in Hyderabad city. The baby's parents were kind enough to overcome the grief and donate their child's organs out of humanity. But, the size



size. It gave new hope to the patient's life. Many aspects

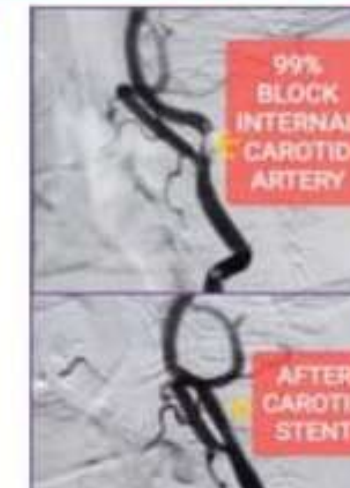
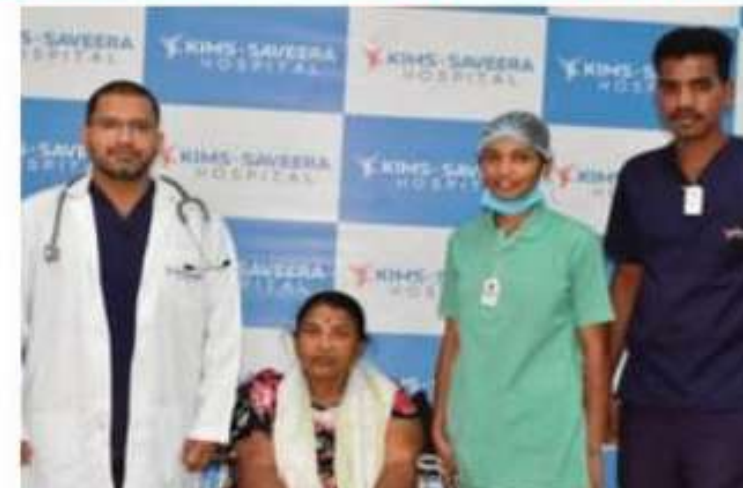donation. But that one decision will save many lives.

Carotid Artery Stenting by Cardiologist

Artery fully blocked and caused brain stroke, Rare treatment is given in KIMS Saveera Hospital

DECCAN NEWS SERVICE
HYDERABAD

The carotid arteries are a pair of blood vessels. There is one on each side of the neck. The carotid artery delivers blood to the brain and head from the heart. We know that Heart attack happens when coronary arteries are blocked. But, an elderly woman suffered from Brain Stroke, due to the complete block write as near total block. KIMS Saveera Hospital doctors of



Kurnool KIMS doctors treat 5-year-old suffering from rare form of seizures

DECCAN NEWS SERVICE
KURNOOL

Have you ever noticed your child staring without responding or daydreaming during activities? This could be a sign of Absence Seizures, which isn't a common occurrence. As a parent, it's important to respond immediately by taking your child to the best medical center. Pranika, a 5-year-old girl from Banaganapalli in the Nandyal district, experienced this issue. Her parents took her to Kurnool KIMS Hospital because she was having seizures 5 to 8 times per day for 2 weeks. These seizures were characterized by a brief staring episode with facial twitching and eye blinking. Dr. Swetha Ramapally, a Pediatric Neurologist, examined and treated the baby in the Aarogyasree scheme completely free, and explained the details of her condition. A young girl named Pranika, whose parents were farmers named K. Venkataramu and M. Venkateswaramma, was experiencing seizures. They brought her to our hospital seeking help. However, this

often stare, her face would twitch, and her eyes would blink for a few moments. After conducting a thorough 3-hour Video EEG evaluation, we discovered that the child had been experiencing multiple seizures in various forms that had gone unnoticed. These included Absence Seizures (staring spells) and nonconvulsive status (seizures that only occur in the brain). Shockingly, there were around 80 to 100 episodes per day that the parents were not able to detect. We have admitted the baby to the hospital. Her brain MRI was normal. Special tests including CSF analysis (spine fluid), blood and urine metabolic tests, and genetic tests were done which were inconclusive. As a part of treatment, she was admitted for about 2 weeks in the hospital. She was treated with escalating doses of multiple anti-seizure medications. During treatment, she had breakthrough convulsions which were managed appropriately. Diet therapy (Modified Atkins diet) was initiated under the supervision of the Dietician. She was given low-carbohydrate, high-fat foods. That was unusual for a 5-year-old.



test results. The food was tested for tolerance too. Eventually child responded to the treatment and it took about 10 days for the seizures to abort. As the parents were farmers, we have provided the entire treatment free under the Aarogyasree Scheme. She suffered from "a rare generalized epilepsy syndrome with frequent absences". We prescribed four types of medicines and diet therapy.

follow-ups for some time. If she doesn't get either normal or absence seizures, the parents can bring her every quarter."

What is this Absence Seizure?

It can be difficult for parents to notice when their child experiences an absence seizure, which is a brief loss of awareness caused by abnormal electrical activity in the brain. This condition is quite rare, affecting only 5-10 children per 100,000. Furthermore, this particular variant is one of the rarest types. Due to the rapid and sudden nature of these seizures, they can be mistaken for daydreaming by observers. Accurate diagnosis can be achieved through a detailed EEG test, which typically lasts between 3 to 8 hours. Absence seizures are typically seen in children aged 4 to 14 and can be a part of either benign epilepsy or a more serious form of epilepsy. However, a major concern with this type of epilepsy is a delay in diagnosis. During a seizure, the child may suddenly stop talking or moving, appearing confused or nervous. These

brain function and lead to serious epilepsy, behavioral changes, sleep disturbances, academic difficulties, and accidents. Therefore, early diagnosis and management of absence seizures are crucial to prevent potential complications, according to Dr. Swetha Ramapally.

My daughter got a second life

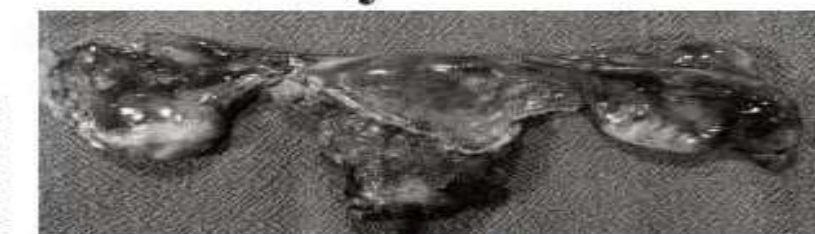"We took our daughter Pranika to KIMS Hospital, Kurnool immediately after noticing seizures. She shouted in the early hours a day before. But we thought that she might have had some bad dreams. She had seizures some eight months back too. Then, it was treated in OP at KIMS Kurnool. Now, our baby was just staring, because of which we were frightened a lot. Dr. Swetha, other doctors, Dieticians, Nurses, and the management of KIMS Hospital all took excellent care of our child. They explained us in detail. We are very thankful to Dr. Swetha, and other doctors who gave second life to our daughter." - Venkata Ramulu, Eka Banika

KIMS docs treat rare reproductive medical condition with only 300 cases worldwide

DECCAN NEWS SERVICE
HYDERABAD

Any male or female person will have different reproductive organs. Though both will be present at the fetus stage, later with the effect of certain hormones, only one will be left. So, by birth itself it'll be decided whether it is a male or female baby. But, in very rare cases, due to the mutation of genes, hormones are not released sufficiently, and the person will have both male and female reproductive organs. It is called Persistent Müllerian duct syndrome in medical terminology. Only 300 such cases are reported worldwide so far. In India, there are only 20 cases till now. Such a rare case came to KIMS hospital in Secunderabad. Consultant Urologist, Uro-Oncho, Andrologist, Relan transplant, and Robotic surgeon Dr. YM Prashant explained the case and treatment given to the patient.

A 40-year-old person from



Manchiryal was suffering from infertility and lower abdominal pain. The local doctors tested on him, and referred the complex case to KIMS hospital. When he came here, we came to know his problem on Ultra Sound Scanning, and MRI tests. He has undescended testis. He appeared physically normal but harbored female internal reproductive organs like the uterus, fallopian tubes, and part of the vagina too. It is called Persistent Müllerian Duct Syndrome. It occurs due to the deficiency of antimüllerian hormone (AMH) activity. Mutation in the AMH gene or



end-organ receptor gene causes this. AMH regresses the Müllerian structures (responsible for female internal reproductive organs) during fetal development in normal males. Its deficient activity leads to persistent Müllerian duct derivatives (internal female reproductive structures along with male). Such people look quite normal. They will have a beard and mustache. Penis will also look normal. But, as the testis don't descend, sperm is not produced. Thus infertility issue arises. On evaluation, the patient was found to have a cystic struc-

ture posterior to the bladder, and prostate attached to the prostate. Testosterone, LH, FSH, and Prolactin hormones are quite normal in the tests. But, his testis is absent in the scrotum, and they are located intra-abdominally. So, Persistent Müllerian duct syndrome is detected and we have decided to take up laparoscopic hysterosalpingectomy surgery. In the process, we have dilated the uterus, a part of the vagina, fallopian tubes, and testes embedded in a broad ligament. We have also dilated the cyst attached to the prostate. The patient is uneventful in the post-operative period, so discharged him on the third day. He was started on quarterly Testosterone replacement. If he could come for the same procedure before the age of 18, he could have the chance of fertility. But now, he doesn't have such a chance. Due to infertility, poverty, and social taboo, such people don't visit proper medical facilities" explained Dr. YM Prashant.

Key Achievements in Q2 FY24

Nanoscopy at KIMS

The surgeons at Krishna Institute of Medical Sciences (KIMS)-Sunshine Hospitals on Wednesday have treated Frozen Shoulder and Rotator Cuff Muscle Tear of the shoulders in patients by employing the novel nanoscopy technology. "Nanoscopy involves a needle camera of size less than 2 mm that allows surgeons to directly view the joint on a screen without cutting the skin with a knife. It is exactly like giving an injection to

New surgery for ankle pain due to osteochondral injury

Orthopaedic trauma team doctors achieve rare feat at Kim's Sunshine Hospital
A rare honour for the first time in South Asia - Dr. Adarsh Annapareddy

DECCAN NEWS SERVICE
HYDERABAD

There are Challenges in Patients with ankle pain and injuries. When nonoperative treatments fail, an endoscopic debridement procedure is used to remove the damaged soft tissue, but this can be combined with a variety of other treatments. Adjunctive therapy may include platelet-rich plasma, cartilage preparation, bone marrow aspirate, bone graft, or whole bone and cartilage graft replacement.

Cartilage injuries in the ankle have very little chance of healing. Due to high pressure in the ankle joint, the cracks formed in the cartilage due to the injury do not heal



by renowned professor Dr. Leif Rid from Sweden at Kims Sunshine Hospital, Secunderabad, for the first time in South Asia, successfully installed a special implant for ankle joint resurfacing for the first time in South Asia. Organized. The surgery started at 8 am on Wednesday and was com-

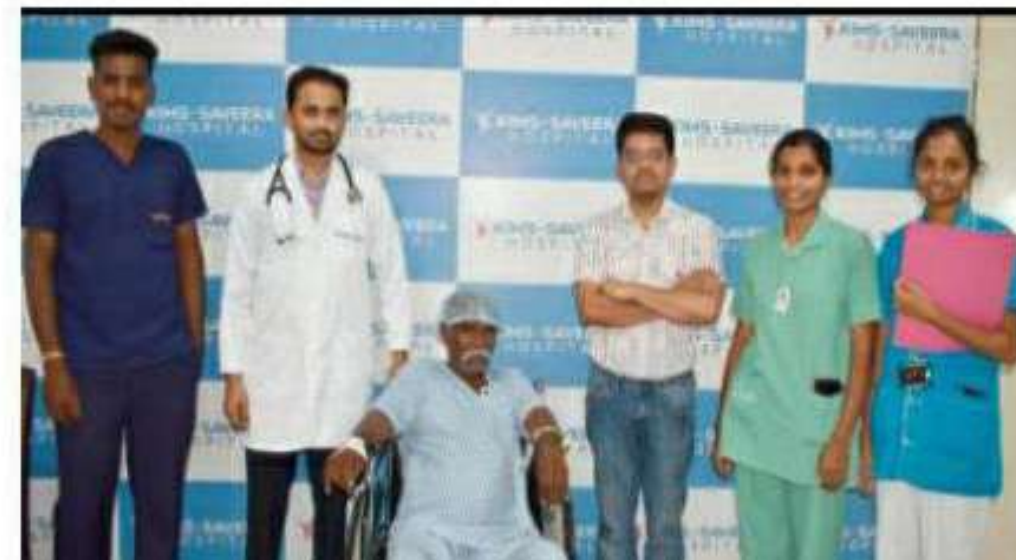

plant is placed in the area to be cut properly. The use of epigu- Secunderabad. Earlier this type of surgery was performed

KIMS Saveera doctors save patient with modern treatment

DECCAN NEWS SERVICE
ANANTHAPURAM

Blocks in the coronary arteries need stenting. But calcification caused it to harden. So, stenting in a regular procedure is just impossible. State-of-the-art treatment is needed in such cases. Doctors at KIMS Saveera Hospitals, Anantapur performed such modern treat-

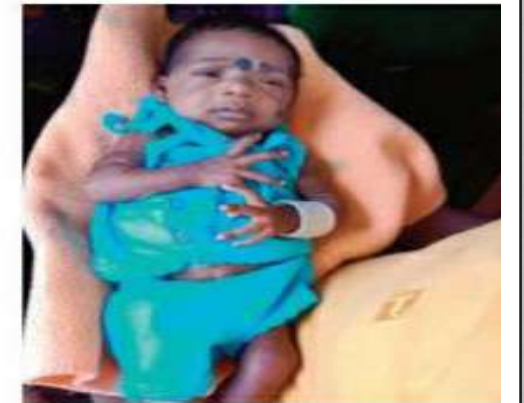

A 10-days-old baby suffers from multi-organ failure KIMS Saveera doctors saved her life

DECCAN NEWS SERVICE
HYDERABAD

A premature baby, who is of 10-days-old was suffering from severe infection and multi-organ failure. Later she got cardiac arrest too. We think of heart attack or cardiac arrest in the case of elders only. But, in this case, the 10-day-old baby got cardiac arrest, and the doctors revived her too. KIMS Saveera Hospital's senior pediatrician Dr. Mahesh explained how they have revived the baby. Jayamma, who belongs to the Kalyandurg area delivered in a private hospital recently. As

dropped to 9000. Blood pumping to the heart is not adequate. Pulmonary edema also formed. In such a condition, at the age of 10 days, the baby was shifted to KIMS Saveera Hospital. The baby's BP was too low at the time of admission. So, we have to keep her on mechanical ventilation for six days. At that time she got a cardiac arrest. So, we did CPR and revived her heart. In normal cases, when all the other organs work properly, CPR can revive the heart. But, in this case, though the baby has multi-organ failure, and is of only 10 days age, we could revive her immediately. We kept



days of meticulous workup and we discharged her. She has to be carefully handled till the age of 2 years. Growth patterns have to be noted. If at all parents find any health issues

లాప్రోస్కోపిక్ పద్ధతిలో కిడ్నీ సేకరణ

- మూత్రపిండాల మార్పిడిలో కర్నూలు కిమ్స్ ఆసుపత్రి చరిత్ర
- కండరాలు, పక్కటెముకలు కత్తిరించకుండానే శస్త్రచికిత్స
- దాతకు ఇబ్బంది తగ్గించేలా సరికొత్త విధానం

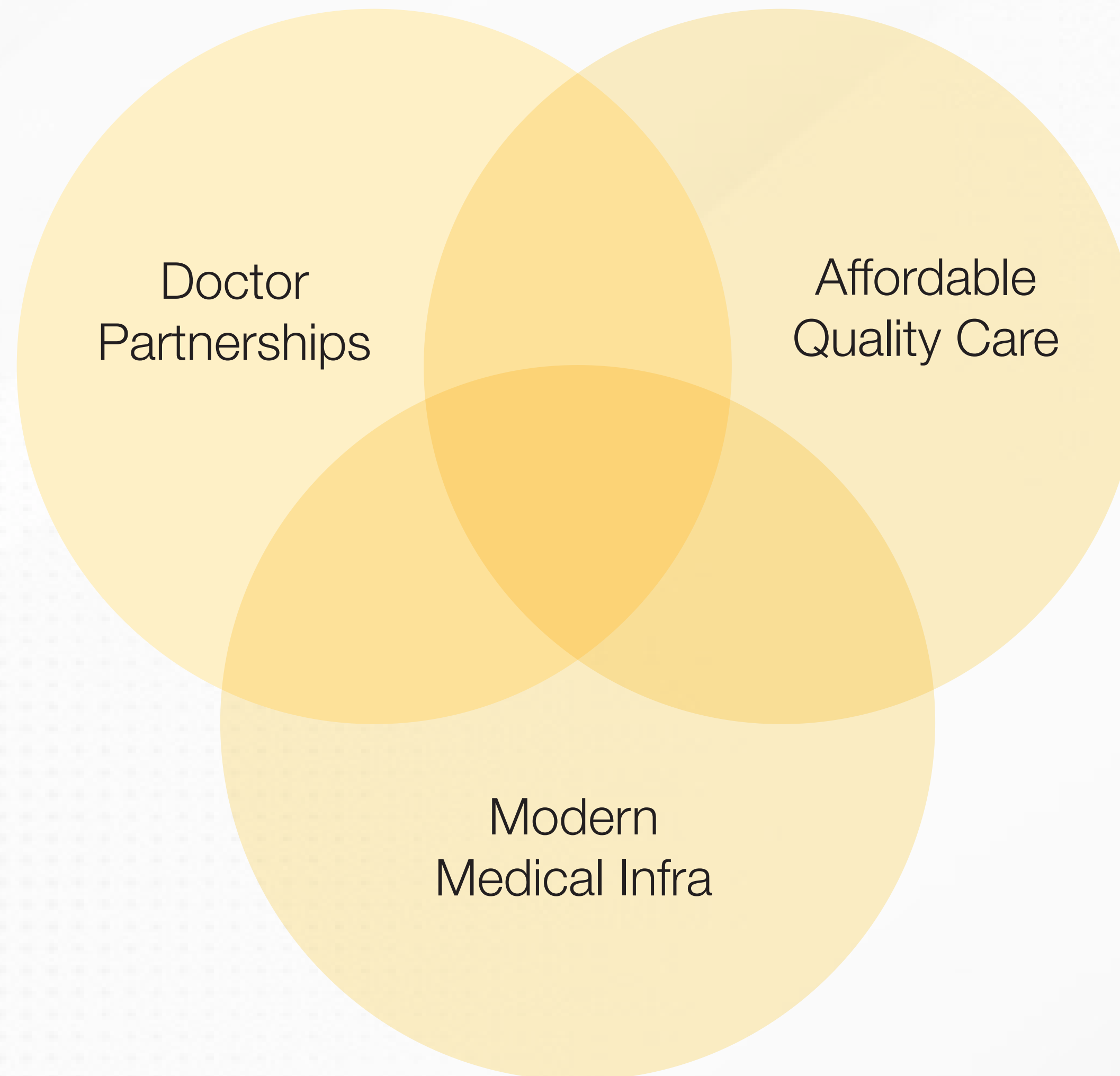


(న్యాయం న్యూస్) జూలై 11 : ప్రతినిధి కర్నూలు, : మూత్రపిండాల మార్పిడిలో దాతకు, గ్రహీతకు ఇద్దరికీ శస్త్రచికిత్స చేయాలి. దాత నుండి సేకరించి, గ్రహీతకు అమర్చాలి. దాత కూడా చాలాకాలం పాటు ఎలాంటి ఇన్ఫెక్షన్లు సోకకుండా జాగ్రత్తలు తీసుకోవాలి. శస్త్రచికిత్స వల్ల నొప్పి కూడా వస్తుంది, ఒంటి మీద పెద్ద పెద్ద మచ్చలు పడతాయి. అదే లాప్రోస్కోపిక్ విధానంలో కిడ్నీని సేకరించగలిగితే ఫలితం చాలా బాగుంటుంది. రాయలసీమలోనే తొలిసారిగా ఇలా లాప్రోస్కోపిక్ పద్ధతిలో దాత నుండి కిడ్నీ సేకరించి గ్రహీతకు అమర్చారు. ఇందుకు సంబంధించిన వివరాలను ఆన్వైత్రీకి

వెందిన యూరాలజిస్ట్ డాక్టర్ మనోజ్ కుమార్ తెలిపారు. "ఇలా చేయడం నిజానికి చాలా సంక్లిష్టం. శస్త్రచికిత్స చేసి, చేరో కిడ్నీ తీయడం చాలా కాలంగా ఉంది. ఆ విధానంలో ఒక పక్కటెముకను కత్తిరిస్తారు. లోపల కండరాలను కూడా కత్తిరించి, అప్పుడు రక్తనాళాలను, మూత్రనాళాన్ని కిడ్నీ నుంచి వేరుచేసి అప్పుడు కిడ్నీని జాగ్రత్తగా అయిటకు తీస్తారు. కానీ దానివల్ల శస్త్రచికిత్స తర్వాత దాతకు విపరీతమైన నొప్పి ఉంటుంది. కత్తిరించిన కండరాలను కుట్టాలి. ఆ గాయాల తగ్గడానికి ఎక్కువ సమయం పడుతుంది. ఈ సమస్యలన్నింటినీ చుట్టూ పెట్టుకుని.. భర్తకు కిడ్నీ ఇవ్వాలనుకు ముందుకొచ్చిన భార్యకు లాప్రోస్కోపిక్ పద్ధతిలో కిడ్నీ సేకరించామని

నివ్వబడింది. కర్నూలు జిల్లాకు చెందిన 40 ఏళ్ల వ్యక్తి చాలాకాలంగా మూత్రపిండాల సమస్యతో బాధపడుతున్నారు. ఆయనకు తన మూత్రపిండంలో ఒకటి ఇన్ఫెక్షన్లు ఆయన భార్య ముందుకొచ్చారు. అన్నీ సరిపోవడంతో అమెరుకు ఇబ్బంది లేకుండా ఉండేలా లాప్రోస్కోపిక్ పద్ధతిలో కిడ్నీ తీయాలని నిర్ణయించారు. ఈ పద్ధతిలో ఎక్కువ పక్కటెముకలను, కండరాలను కత్తిరించాల్సిన అవసరం ఉండదు. కేవలం ఫేషియా అనే ఒక పొరను మాత్రం కత్తిరించి, మూత్రపిండానికి ఎలాంటి గాయం కాకుండా అత్యంత జాగ్రత్తగా సేకరిస్తారు. చుట్టుపక్కల రక్తనాళాలకు కూడా ఇబ్బంది లేకుండా చేస్తారు. ఉదాహరణకు కిందివాగంలో చిన్నపాటి కోతల ద్వారానే సేకరిస్తారు. దీనివల్ల నొప్పి చాలా తగ్గుతుంది. ఇలా చేయడంతో దాత రెండు రోజుల్లో లేచి తిరిగి, మూడోరోజు రిల్యాన్స్ కూడా అయ్యారు. కిడ్నీ ఇచ్చిన దాత 35 ఏళ్ల వయసున్న మహిళ కావడంతో శరీరం మీద ఎలాంటి మచ్చలు లేకుండా చేయగలిగారు. కేవలం 1 సెంటీమీటరుని ఒకటి, అర సెంటీమీటరుని రెండు చిన్న కోతలు మాత్రమే ఉండటం వల్ల చూడటానికి కూడా ఎలాంటి ఇబ్బంది ఉండదు. ఈ శస్త్రచికిత్సలో దా. ఉమాపాళ్ళరావు, ఆనన్దప్రసాద్ డాక్టర్లు శ్రీతి మరియు భువనేశ్వరి, సైక్లోజిస్ట్ డా. అనంతరావులు పాల్గొన్నారు. రాయలసీమ ప్రాంతంలోనే ఇలా లాప్రోస్కోపిక్ పద్ధతిలో మూత్రపిండం సేకరించడం ఇదే తొలిసారి" అని ఆయన వివరించారు

Key to our success



KIMS has a disciplined growth strategy - strategically grow in adjacent markets some of which are 'natural extensions'

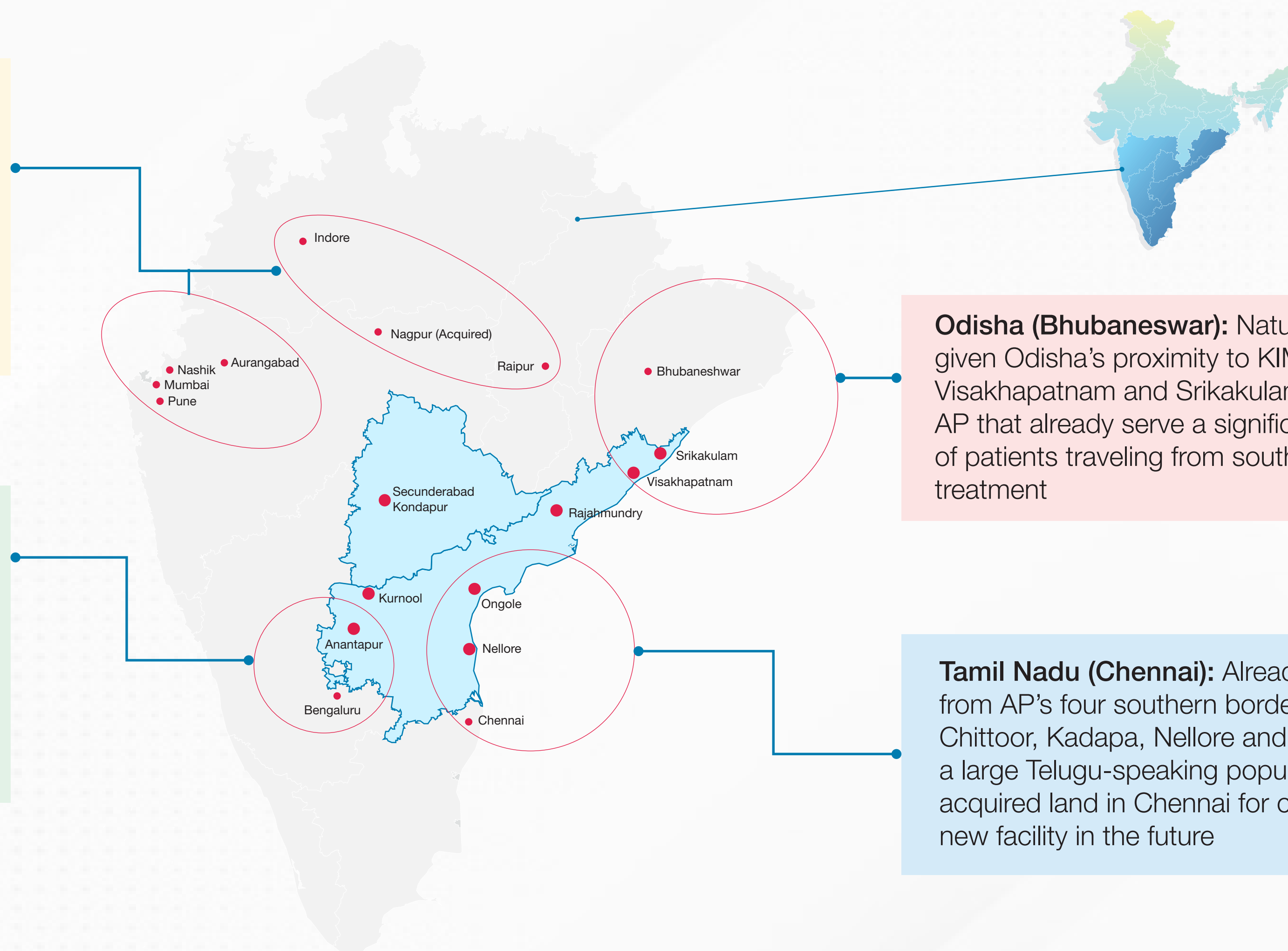
KIMS Plans to Grow into Markets that are Adjacent to the Current Core Markets of AP and Telangana

Central & Western India (Mumbai, Indore, Aurangabad, Nagpur & Raipur): KIMS flagship hospital witnesses influx of patients and doctors from Central India. Given scarcity of quality healthcare and existing KIMS brand awareness in Central India, smaller facilities can be set up in Central India

Karnataka (Bangalore and greater Karnataka): KIMS has observed both cash patients and insurance patients traveling from the districts of AP bordering Karnataka to seek treatment at larger hospitals in Bangalore (Karnataka). Karnataka is a natural growth market because a sizeable portion of the state speaks Telugu - the main language spoken in AP and Telangana

Odisha (Bhubaneswar): Natural extension given Odisha's proximity to KIMS hospitals in Visakhapatnam and Srikakulam in northern AP that already serve a significant number of patients traveling from south Odisha for treatment

Tamil Nadu (Chennai): Already attracts patients from AP's four southern border districts of Chittoor, Kadapa, Nellore and Ongole and has a large Telugu-speaking population. KIMS has acquired land in Chennai for construction of a new facility in the future



Expansion plans

Units	Current Beds	Incremental Beds	New Departments	Approx. Capex	Expected Year of Operation
Nashik	-	300	All Specialities	200-250 Cr	Q1 FY25
Mumbai (Thane)	-	300	All Specialities	225-250 Cr	Q4 FY25
Bangalore	-	415	All Specialities	350-400 Cr	Q4 FY25
Anantapur	250	200	Cancer Centre / Mother & Child	90-110 Cr	Q4 FY26
Kondapur	200	500	All Specialities	300-350 Cr	Q1 FY27

Profit and Loss Statement

(Rupees in Millions)

	Consolidated							
Particulars	Q2 FY 24	Q1 FY 24	Q2 FY 23	QoQ(%)	YoY(%)	H1 FY 24	H1 FY 23	YoY(%)
Operating Revenue	6,525	6,060	5,641	7.7%	15.7%	12,585	10,596	18.8%
Other Income	29	31	92	-7.3%	-68.6%	60	145	-58.7%
Total Revenue	6,554	6,091	5,733	7.6%	14.3%	12,645	10,741	17.7%
EBITDA*	1,723	1,548	1,447	11.3%	19.1%	3,270	2,759	18.5%
EBITDA (%) on operating revenue	26.4%	25.5%	25.7%			26.0%	26.0%	
PBT**	1,386	1,186	1,226	16.9%	13.0%	2,572	2,300	11.8%
PBT (%) on total revenue	21.2%	19.5%	21.4%			20.3%	21.4%	
PAT**	1,013	867	912	16.9%	11.0%	1,880	1,705	10.3%
PAT (%) on total revenue	15.5%	14.2%	15.9%			14.9%	15.9%	
Basic EPS (Rs.)	11.5	10.1	12.1	13.9%	-5.3%	21.6	20.9	3.4%
Diluted EPS (Rs.)	11.5	10.1	12.1	13.9%	-5.3%	21.6	20.9	3.4%
IND AS	49.9	23.1	77.3			73.1	136.7	

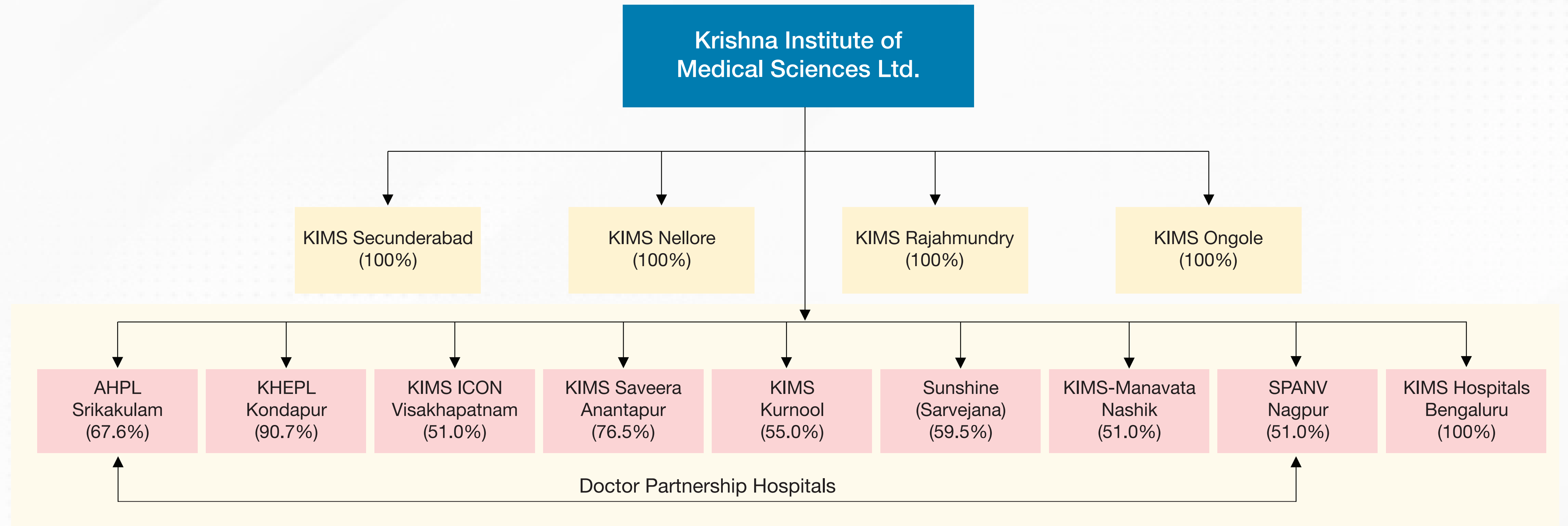
Minority share of EBITDA for Q2 FY24 stands at 12.6%

*EBITDA before IND AS and other income

**PBT and PAT are excluding items of:

- 1) Associates share of profit of Rs. 95.1 Mn in FY22
- 2) Fair value gain on aquisition of control of Rs. 148.3 Mn in FY23
- 3) Share of loss of associate of Rs.0.22mn in Q2 FY24

Corporate Structure (As on 30th September'23)



Thank You